

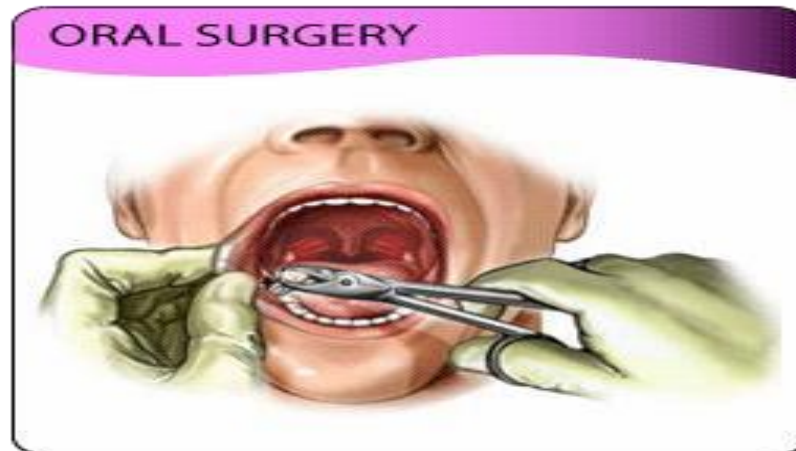Academic Year 3



Principles of Complicated Exodontia

Dr. Hamid Hammad Enezei

Ph.D in Oral & Maxillofacial Surgery



Objectives:

1-Understand the technique of:

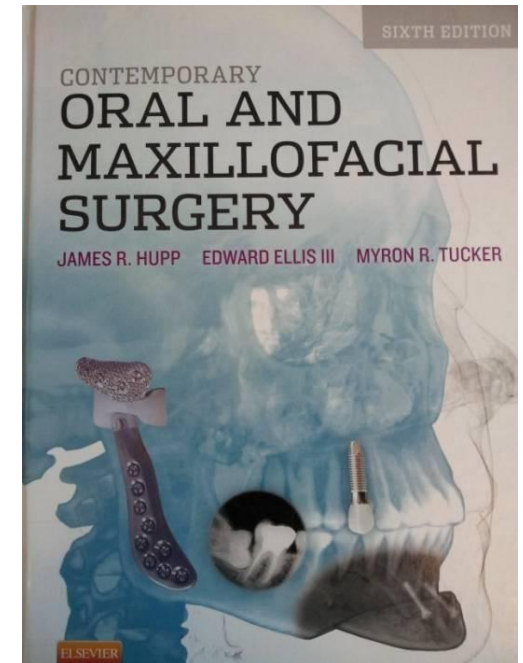

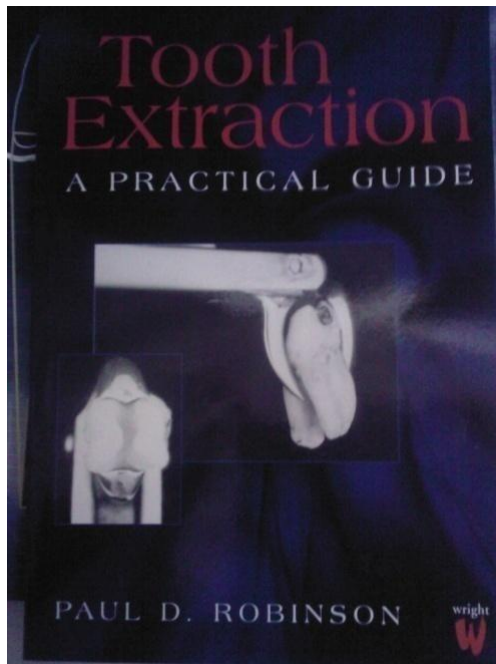
A- Extraction of single-rooted teeth with destroyed Crown.

B- Extraction of multi-rooted teeth with destroyed Crown.

C- Root tips extraction.

2 List the indications and contraindications for surgical tooth extraction.

3 Outline the steps of surgical extraction of tooth / root.



Further reading

Fragiskos D. Fragiskos (2007): Oral Surgery. Springer

Robinson (2007): Tooth Extraction-A Practical Guide. Wright

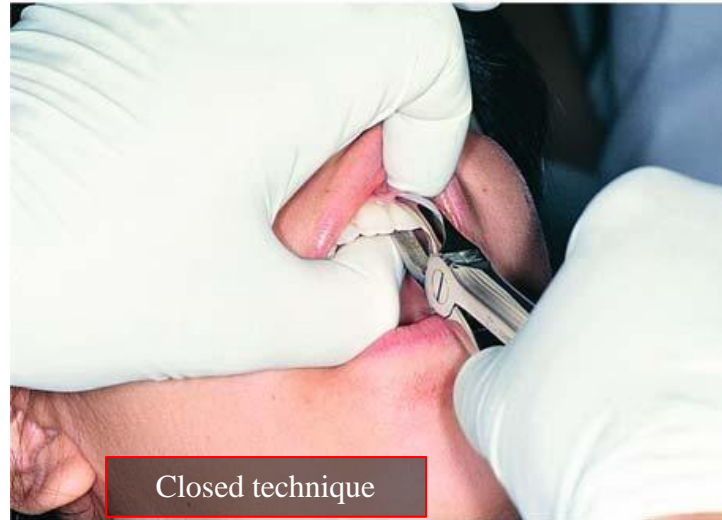H²upp(2014), Contemporary Oral and Maxillofacial Surgery. Elsevier

Methods of Tooth Extraction

Erupted teeth could be extracted by two ways:

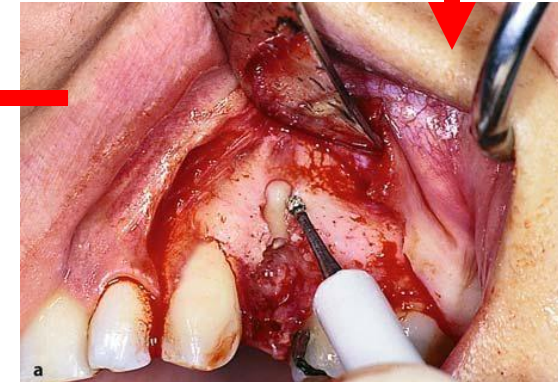
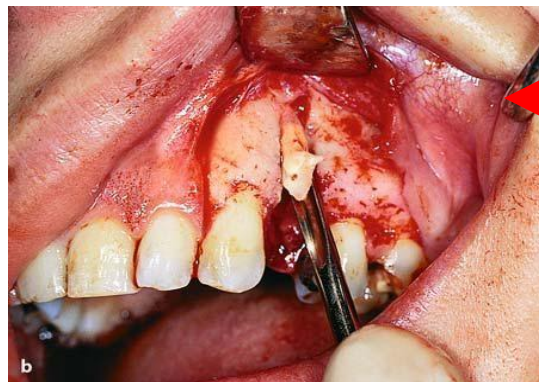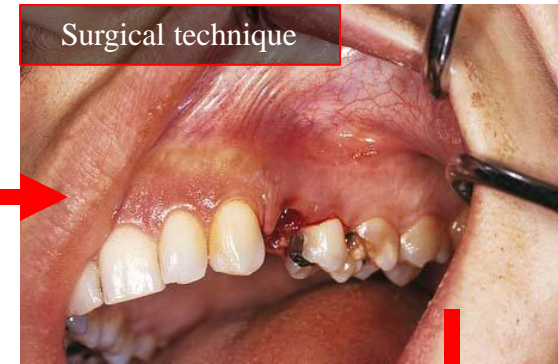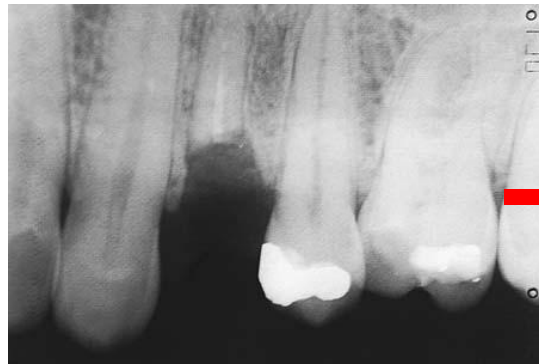1- The closed technique (routine)

The most frequent technique.



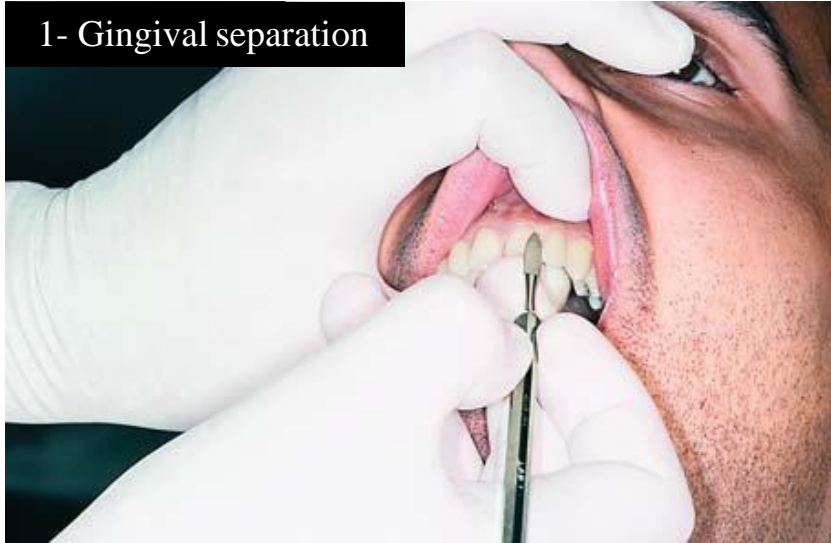2- The open technique (flap or surgical)

It is indicated when the routine method fails to extract the tooth.

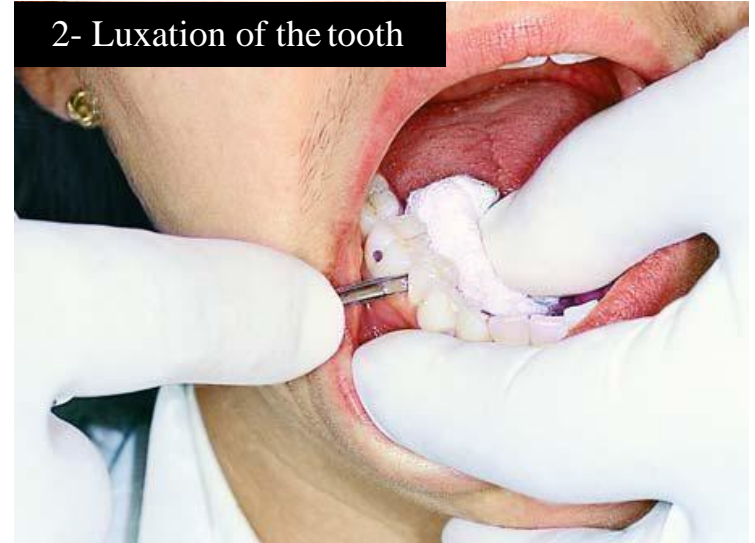


Clinical Steps of the Closed Extraction Technique

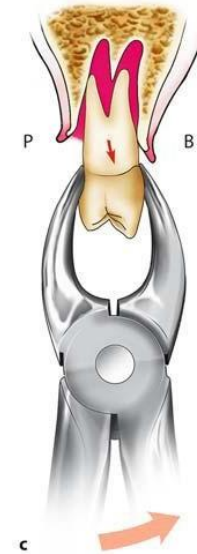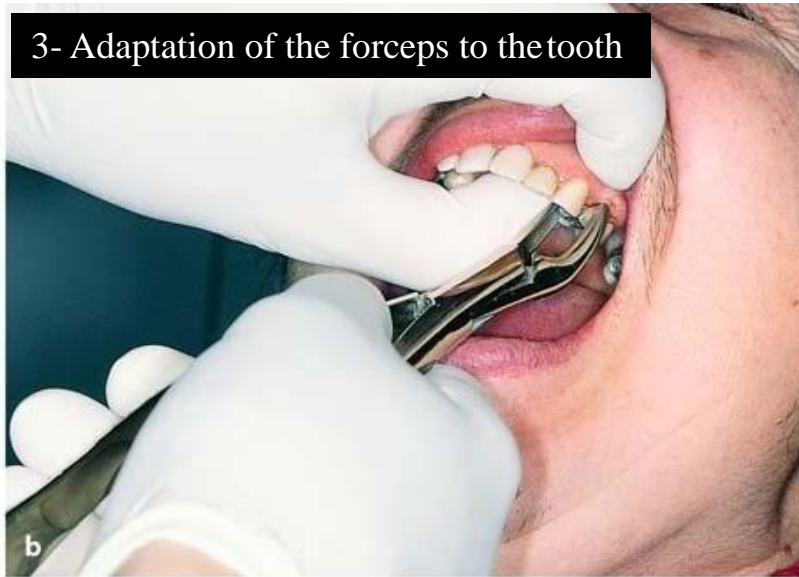
1- Gingival separation



2- Luxation of the tooth



3- Adaptation of the forceps to the tooth



4- Buccal and lingual pressure, with traccional force buccally

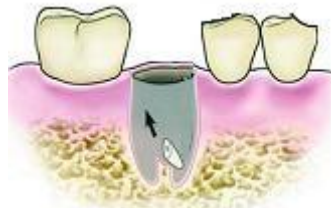
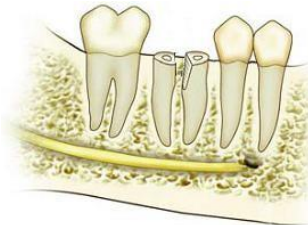
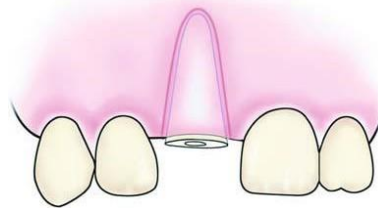
Complicated Extraction

Difficult cases but still removed by non surgical means

A- Extraction of Single-Rooted Teeth with Destroyed Crown

B- Extraction of Multi-Rooted Teeth with Destroyed Crown

C- Extraction of Root Tips



Difficult cases need Surgical Extraction

A- Tooth Extraction

B- Root Extraction

Extraction of Single Rooted Teeth with Destroyed Crown

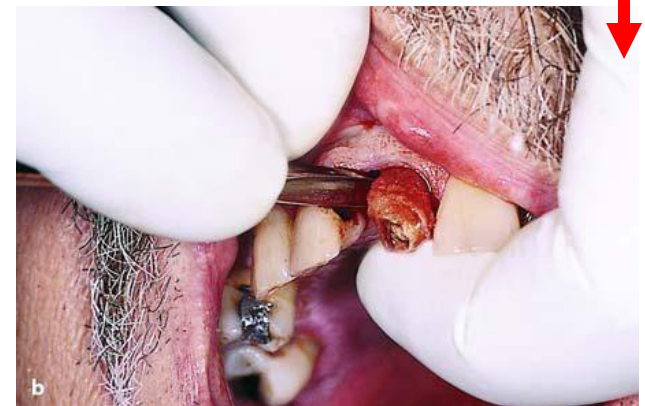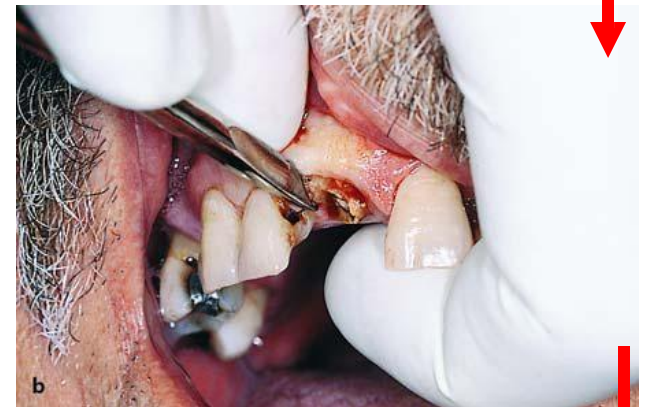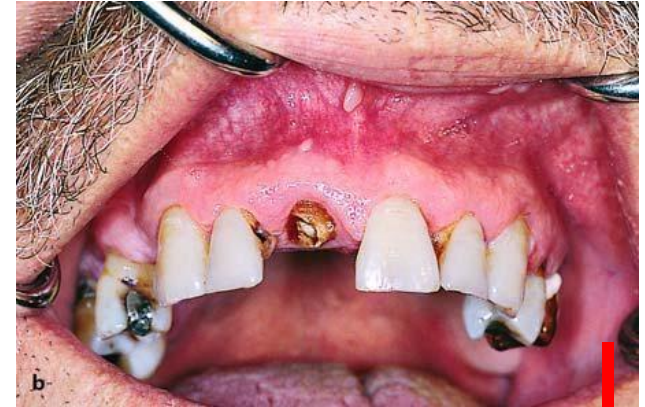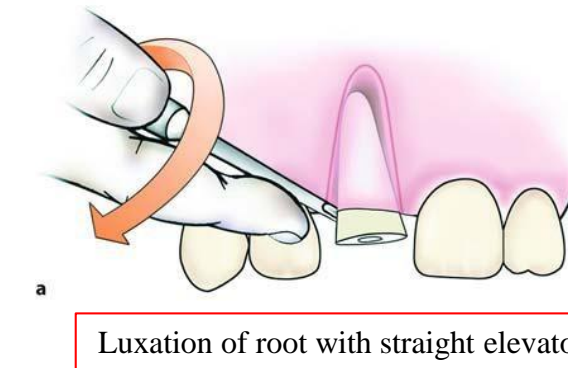
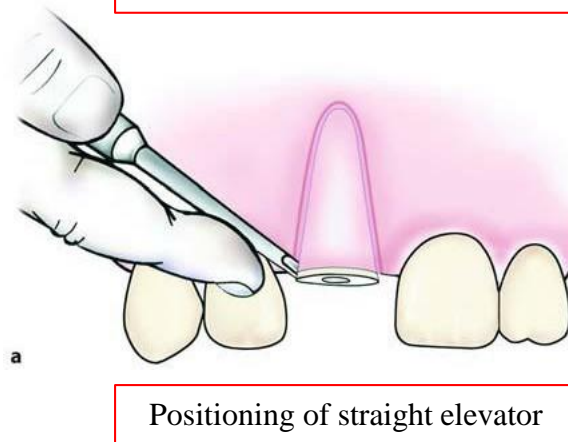
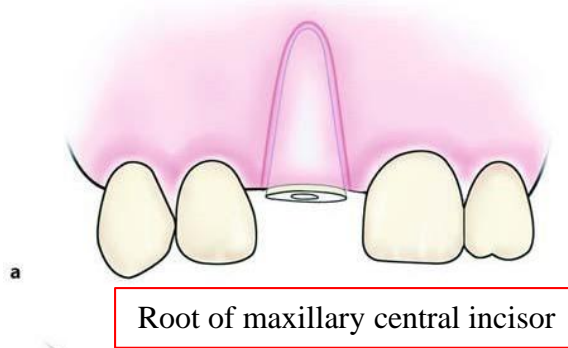
1- It is accomplished with the help of the straight elevator.

2- The blade of the elevator is seated between the root and alveolar bone, with the concave surface of the blade in contact with the mesiobuccal or distobuccal corner of the root.

3- Using the alveolar bone as a fulcrum, rotational forces are applied around the axis of the elevator, resulting in displacement of the root out of the socket.

Indication:

When the root could not be removed by root forceps & the shape is favorable, and its level is above or with the level of the bone.



Extraction of Single Rooted Teeth with Destroyed Crown

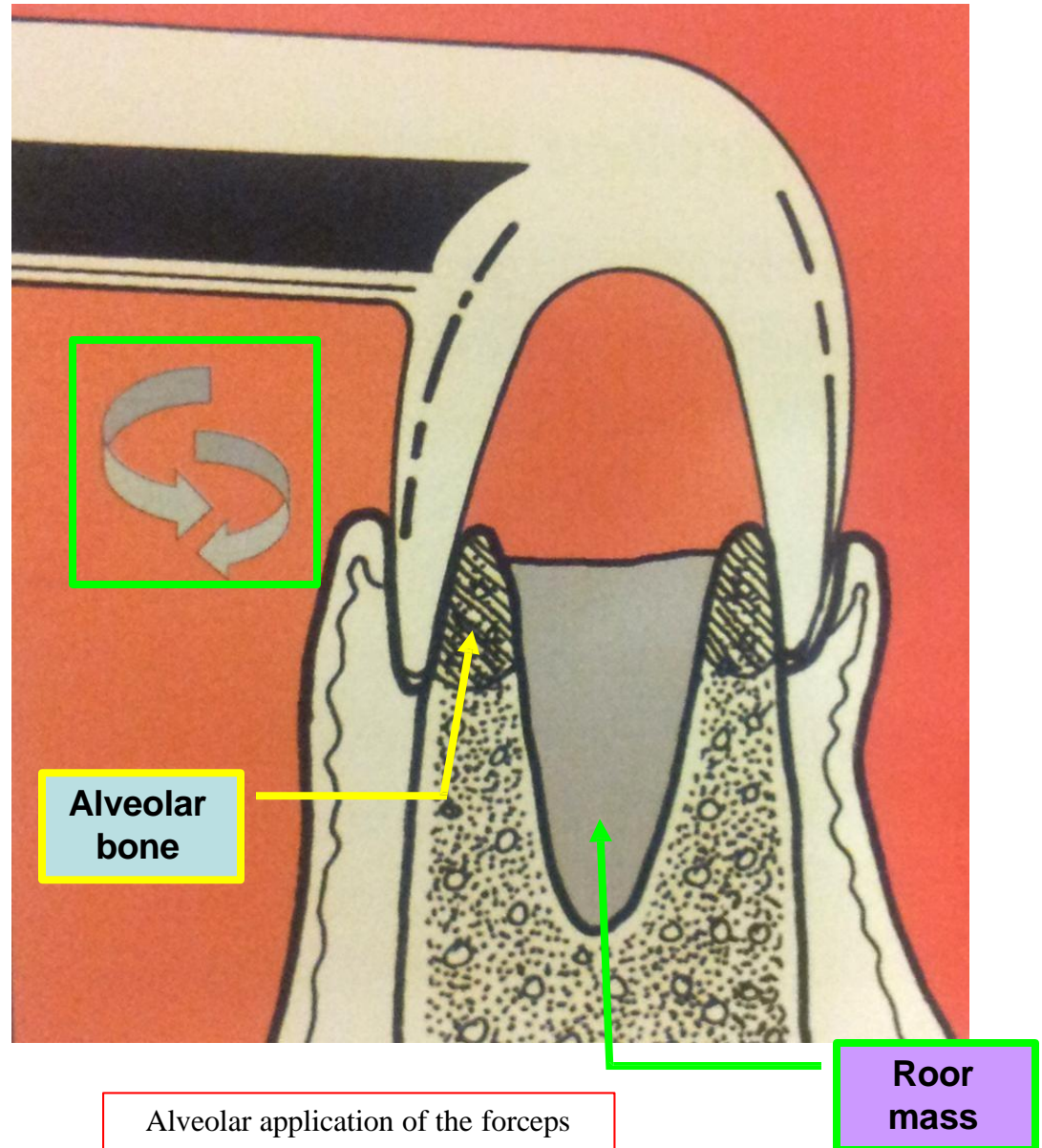
4- Sometimes a small portion of the alveolar bone may be grasped with the root forceps and the root then is removed along with that small portion of the alveolar bone (alveolar application of the forceps).

Note:

If you are planning to place an implant, this procedure is not recommended since the bone is very precious in implant surgery.

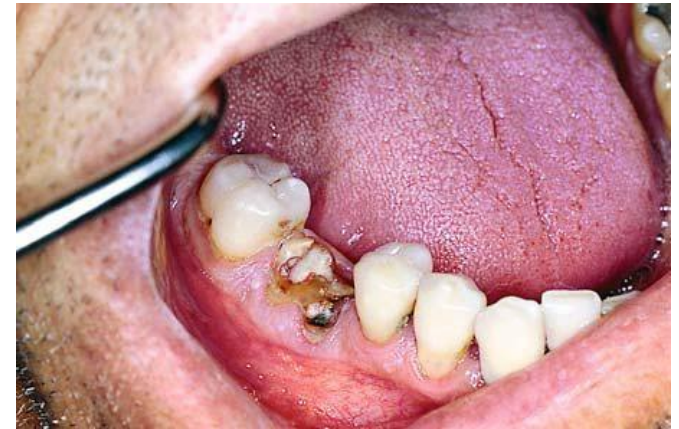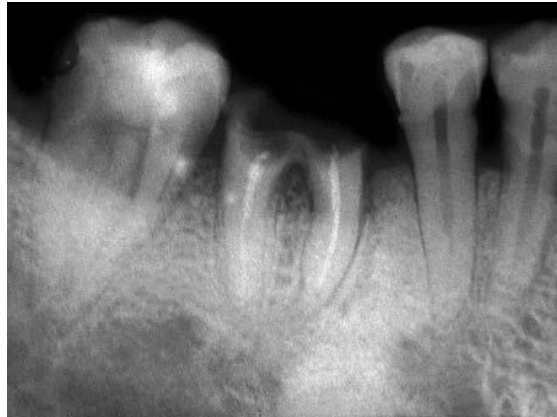Indication:

When the root could not be grasped by root forceps & the shape is favorable, and its level is with or little below the alveolar bone.



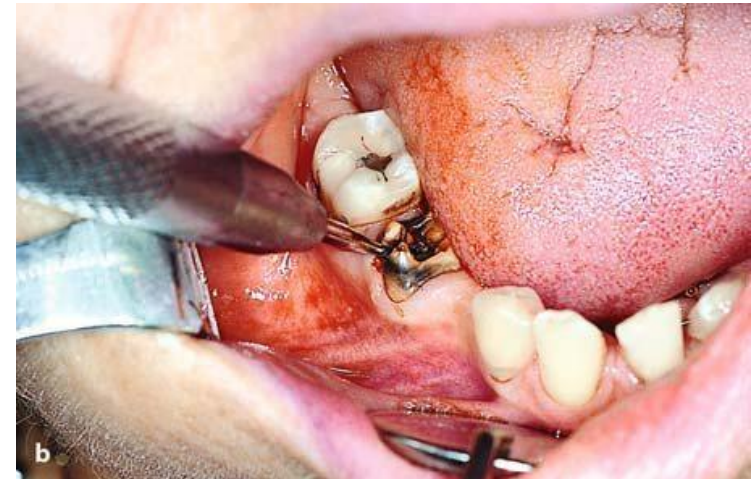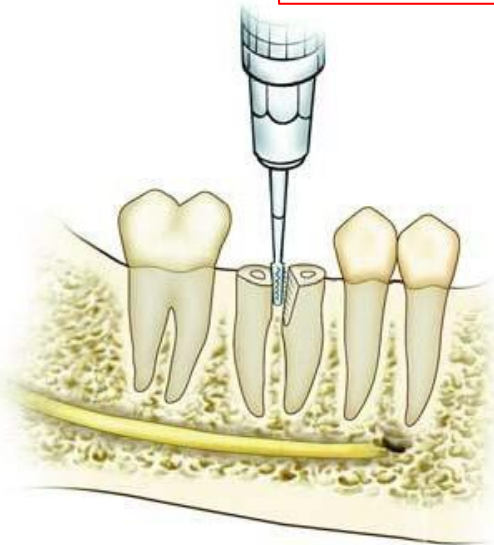
Extraction of Multi Rooted Teeth with Destroyed Crown

1- It is achieved by root separation.



Mandibular first molar with destroyed crown

2- The roots are sectioned and separated after creating a deep perpendicular buccolingual groove using a fissure bur, which reaches the intraradicular bone.

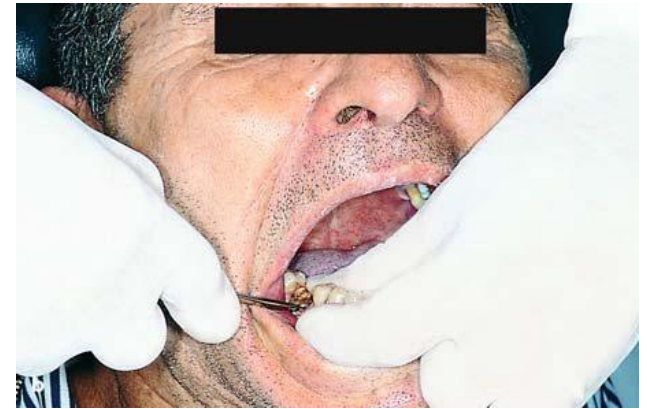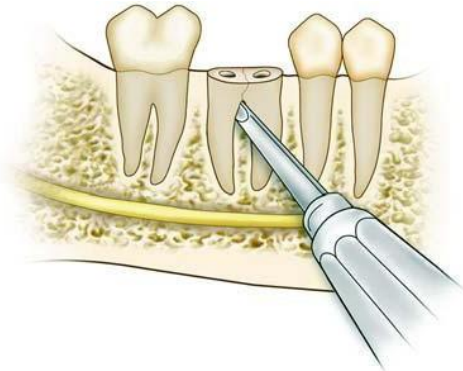


Separation of roots of the mandibular first molar with fissure bur

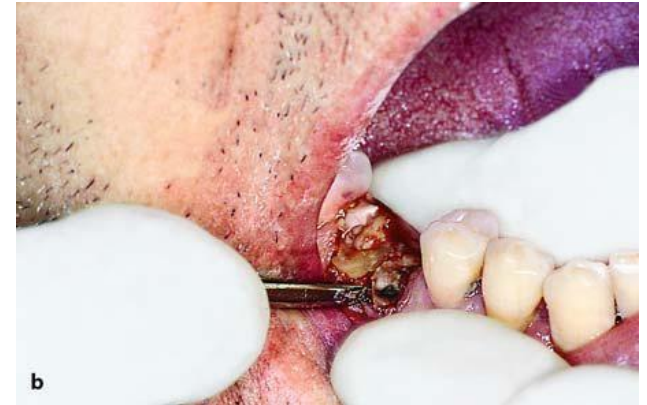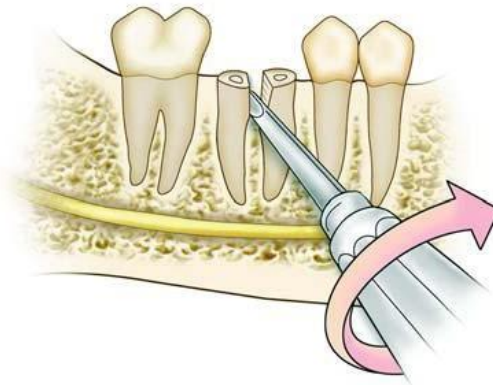
Indication:

When you can not get grasp by forceps & the roots shape is favorable, and its level is above or with the level of the bone.

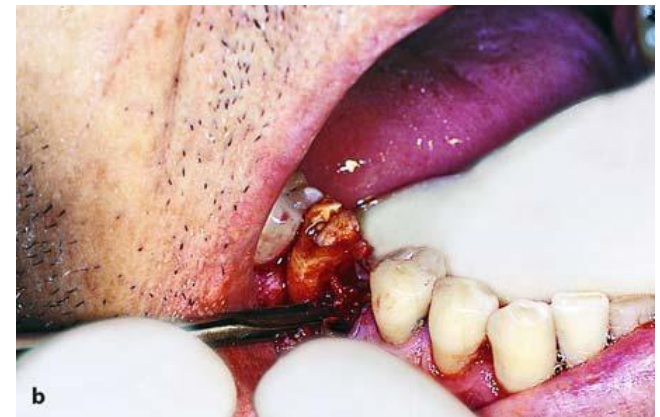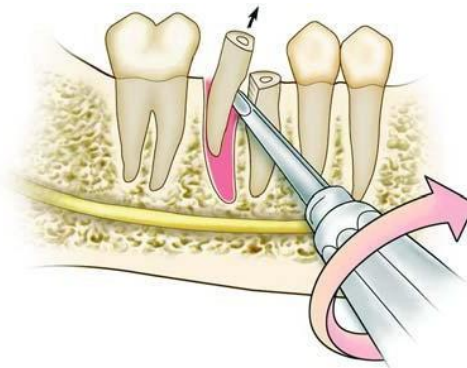
3- Sectioning may also be accomplished using the straight elevator, after placing its blade in the root bifurcation.



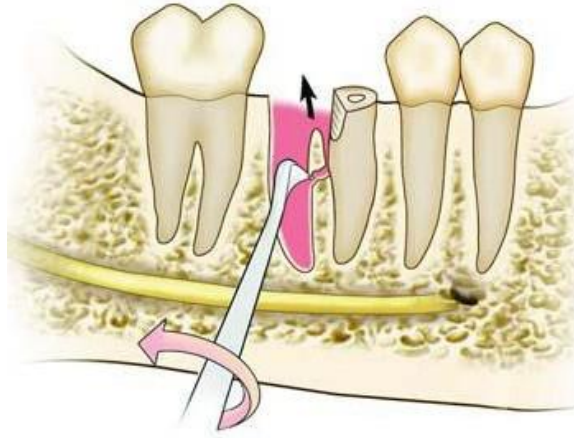
4- The roots then separated by employing rotational movements.



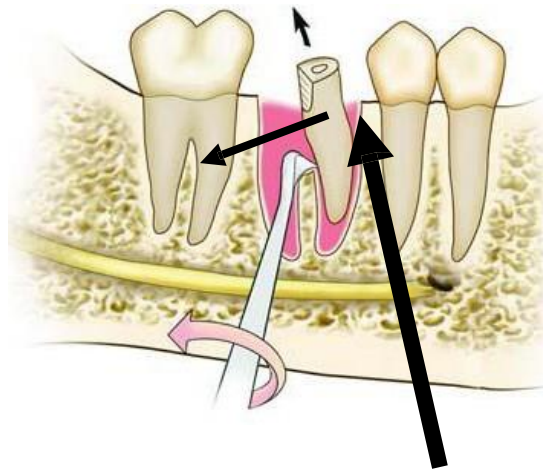
5- At the same time by this rotational movement, one root could be elevated easily from its socket, otherwise root forceps could be used to remove each root separately.



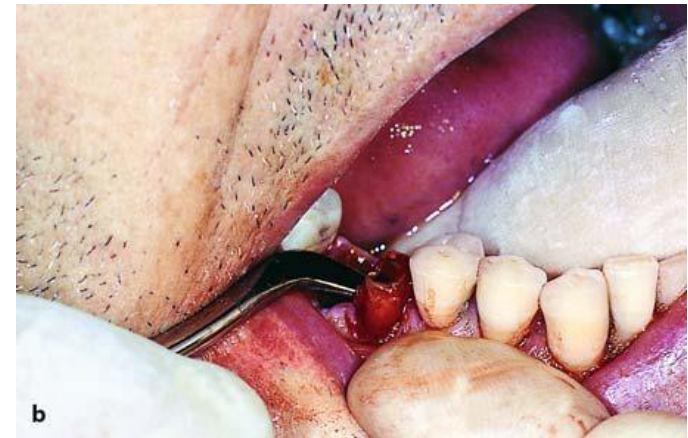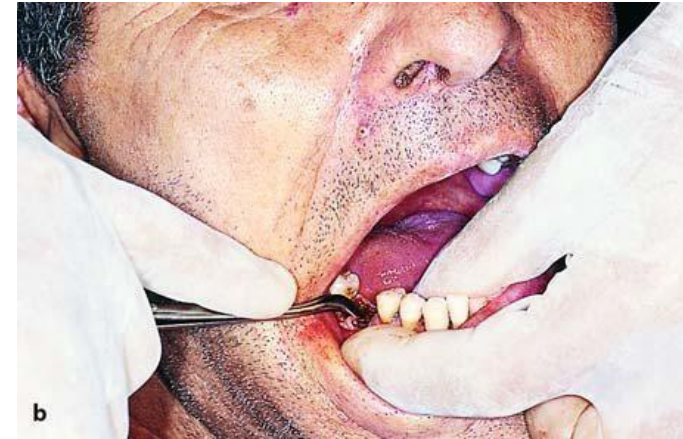6- The other root may then be removed using the cryer's elevator.



7- The elevator is placed so that the blade is positioned in the empty socket with its end facing the root. The intraradicular bone is removed first (if it is higher than the root) and then the tip of the elevator comes into contact with the root, which is removed after applying rotational pressure upwards.



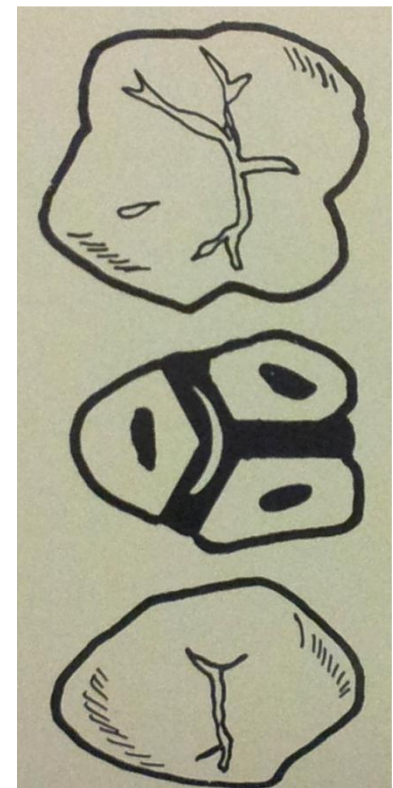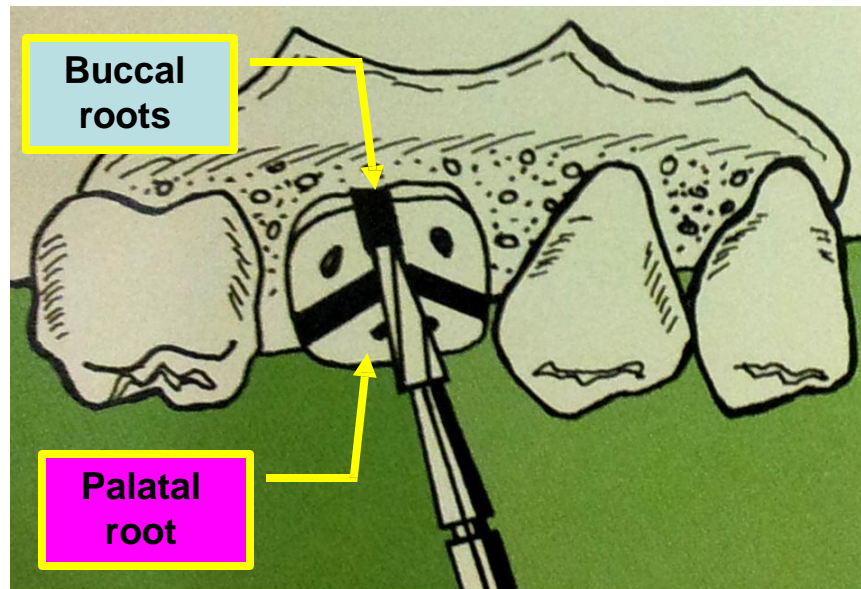
Note:
In this example, Straight elevator could be used by placing it in the mesial corner of the root and pushing it toward distal socket.



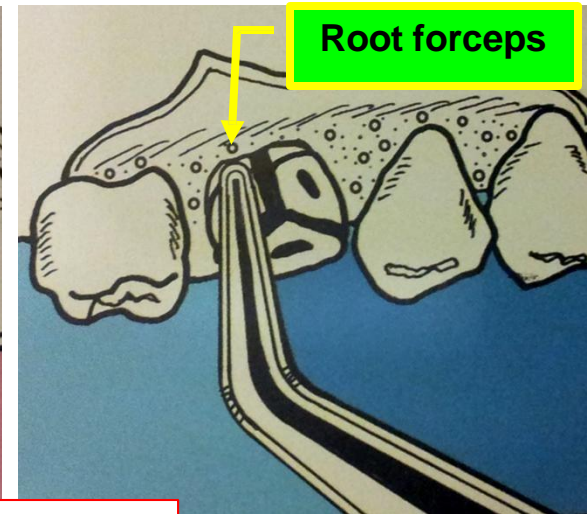
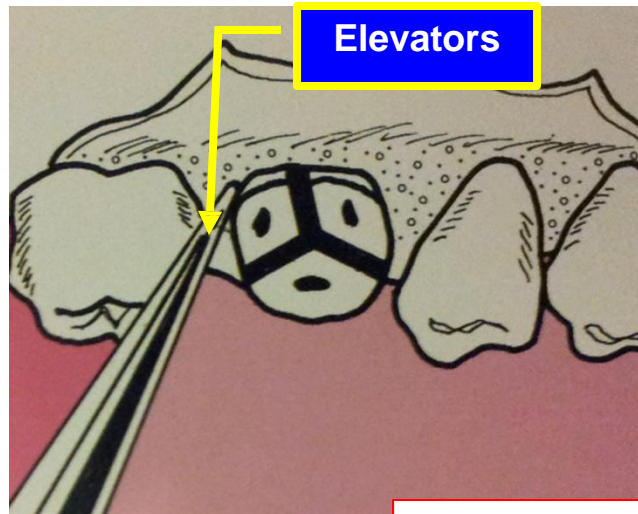
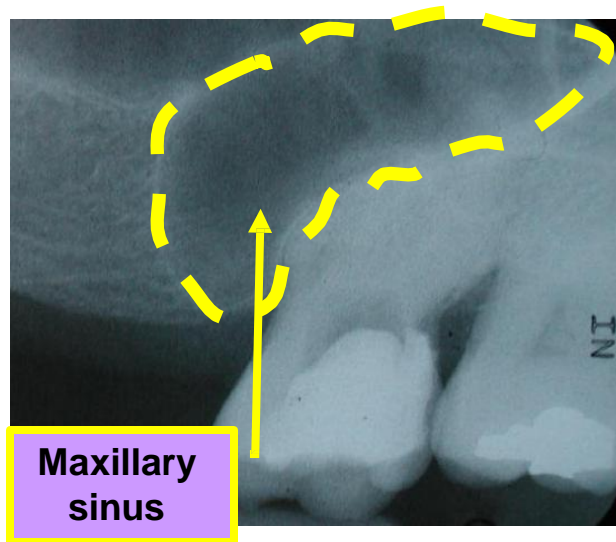
8- For upper molars (have three roots), the roots are sectioned, first separate palatal from buccal roots, then section the buccal roots into mesiobuccal and distobuccal one. Sectioning either by bur or elevator. Then each root is removed separately by elevator or root forceps.

Note:

During sectioning of the roots by bur, attention should be given not to extend the bur deep since maxillary sinus sometimes extends into the furcation area of the tooth.



Roots sectioning



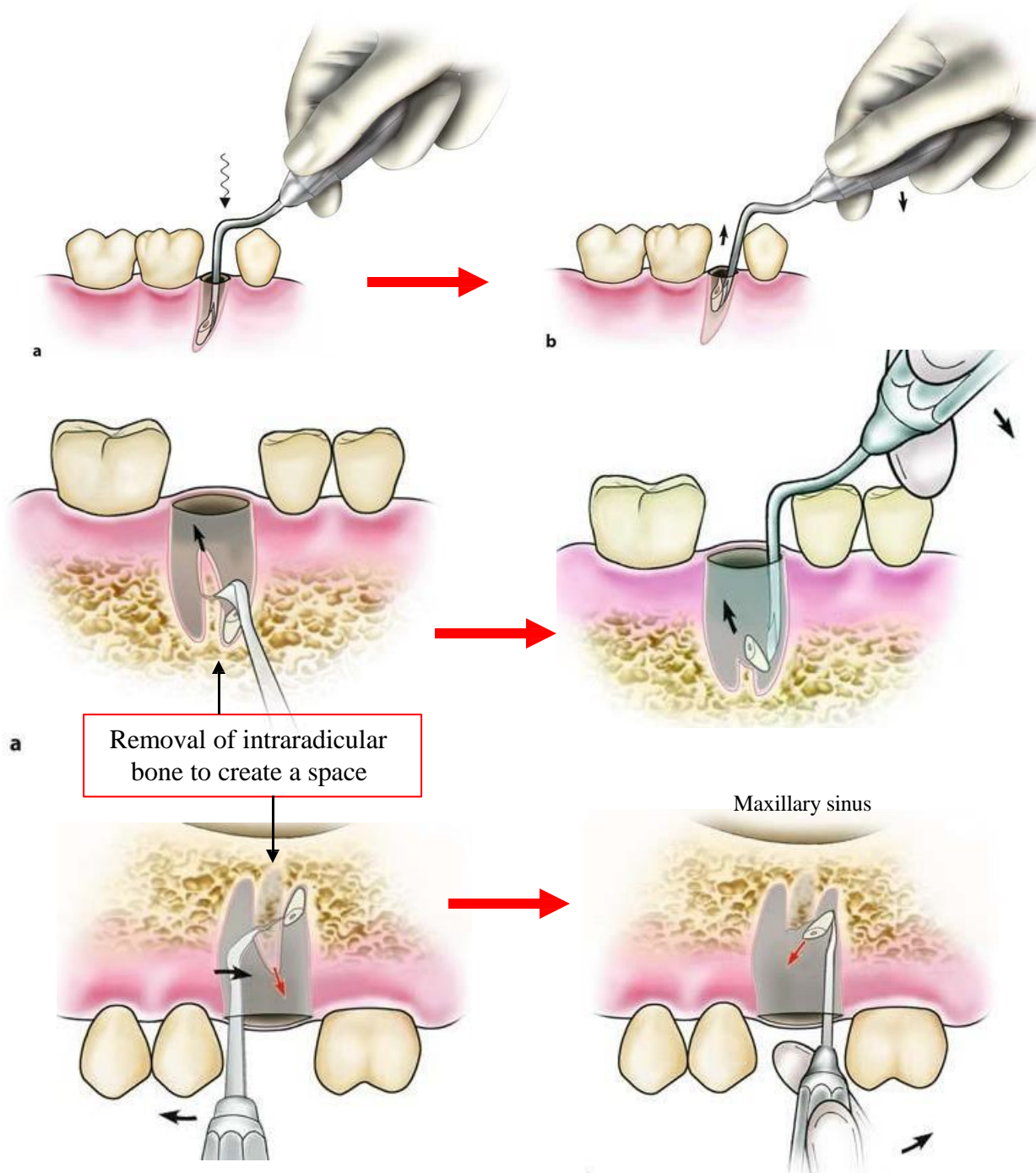
Roots removal

Extraction of Root Tips

1In order to extract root tips from the maxilla and mandible, fine apexo elevator (with narrow blade) is the most appropriate instrument, due to its sharp tip, which fits easily between the root tip and the alveolar bone, luxating the root tip from the socket.

2Sometimes extraction of the root tip requires part of the intraradicular bone should be removed from inside the socket with a round bur or sharp instrument, creating room that will facilitate its luxation.

3- Special care required for extraction of root tips of upper posterior teeth because there is an increased risk of displacing the root tip into the maxillary sinus.



4- The root tip may also be removed with the aid of an endodontic file, which is positioned inside the socket and then screwed into the root canal, upon which the root tip is delivered either by hand or with a needle holder.

When a needle holder is used, a protective gauze may be placed between it and the occlusal surface of the teeth on which it rests.

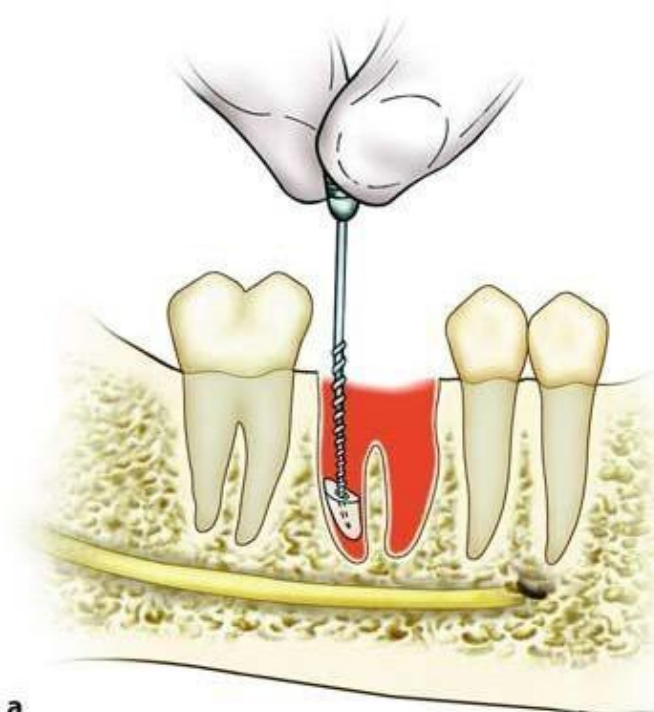
Note:

This procedure is difficult to achieve unless we get primary mobility of the root before it gets fracture with good visibility of the field and the root has visible root canal.

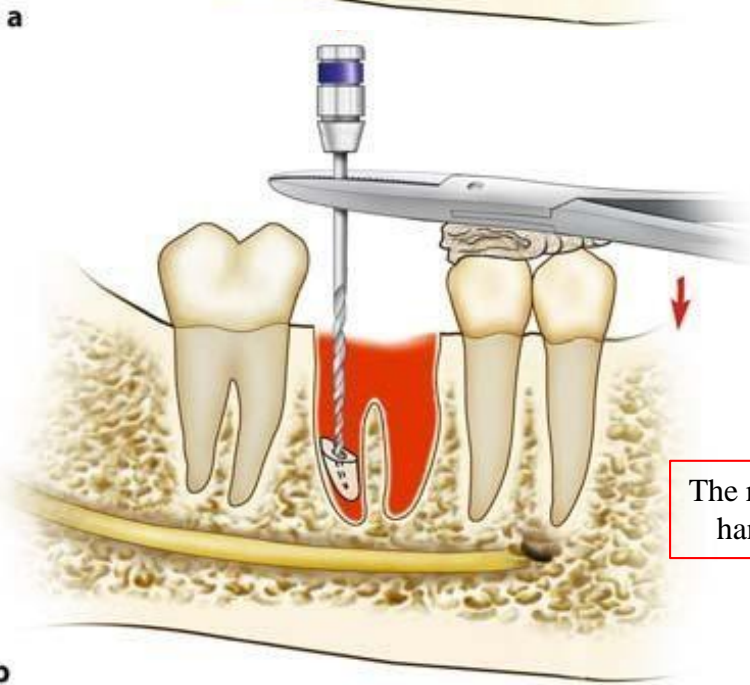
5- Irrigation –Suction Technique:

This technique is useful when the tooth was well luxated and mobile before the root was fractured.

The socket is irrigated vigorously and suctioned with fine suction tip.



Endodontic file enters the root canal



The root tip is drawn upwards by hand or with a needle holder

Surgical Extraction of Tooth / Root

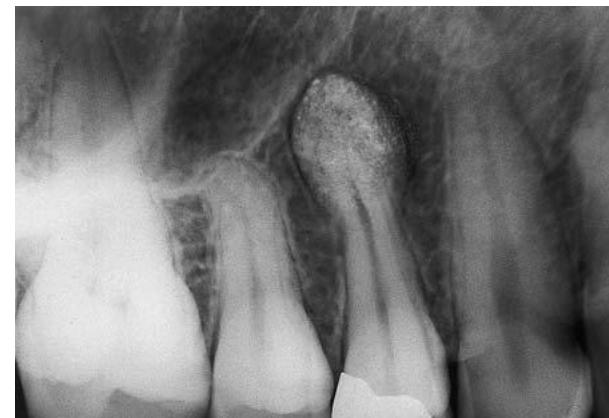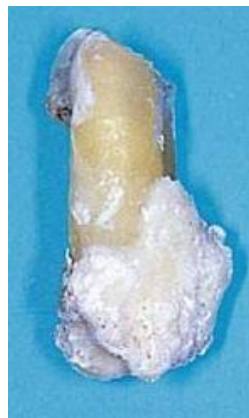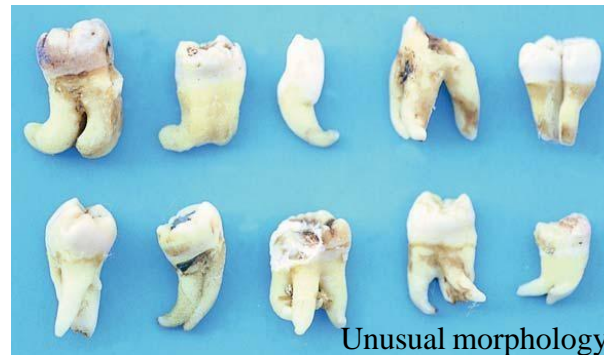Indications:

1- Teeth with unusual root morphology. Because their removal with the conventional technique will result in complications (e.g. root fracture or alveolar bone fracture).

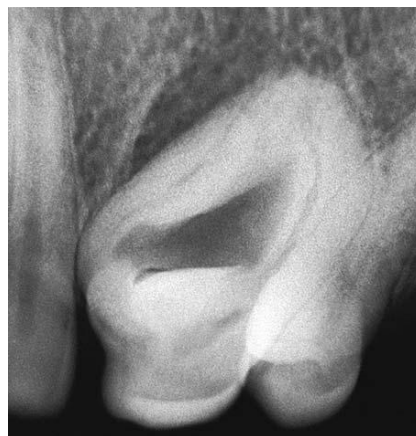2- Teeth with hypercementosis of root or with large bulbous roots.

3- Teeth with dilaceration of root tips.

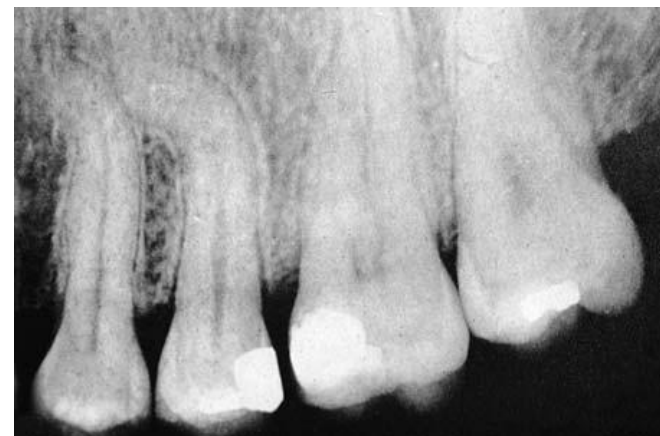4- Teeth with ankylosed roots or with abnormalities, e.g., dens in dente.



maxillary premolar with hypercementosis at root tip



Dens in dente of maxillary canine

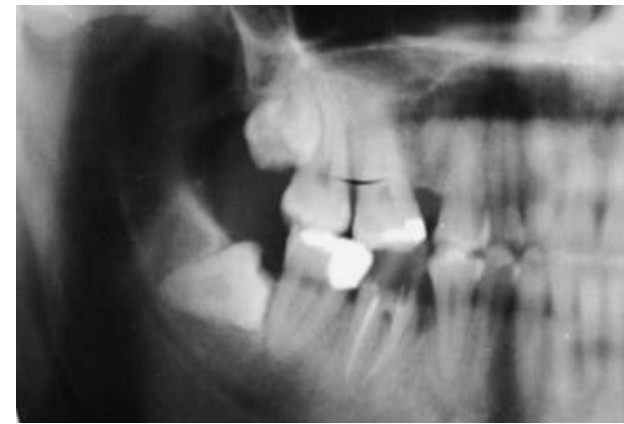

Root tips of second premolar, with nearly right angle curvature

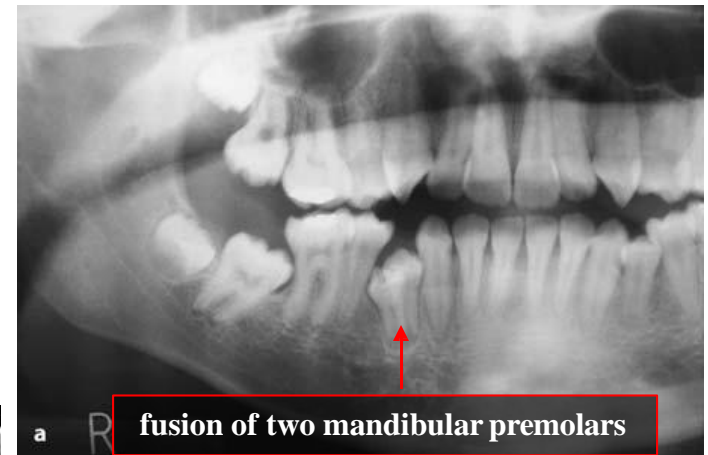
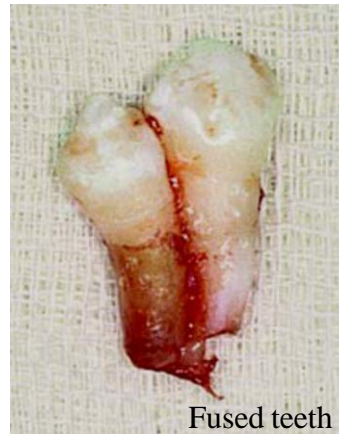5 Impacted and semi-impacted teeth.

6 Fused teeth. If extraction done by conventional technique, then part of the alveolar process could be fractured or removed together with the teeth.

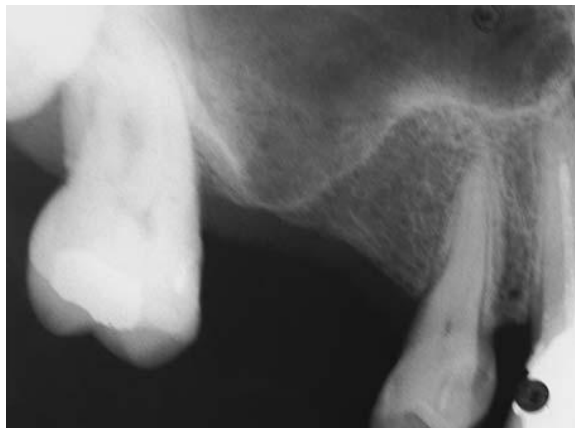7- Maxillary posterior teeth, whose roots are divergent and included in the maxillary sinus or in case of pneumatization of the maxillary sinus (the maxillary sinus extends as far as the alveolar ridge).



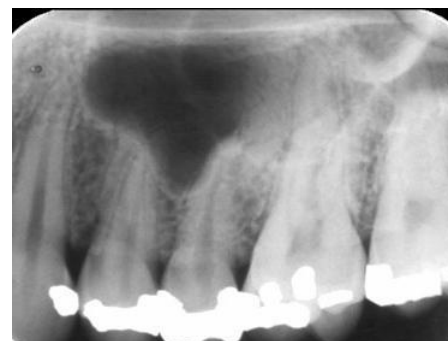Semi-impacted mandibular third molar



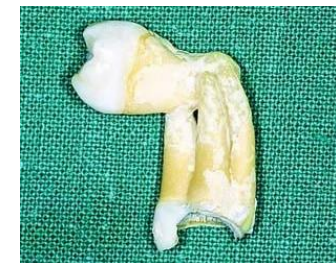fusion of two mandibular premolars



Pneumatization of the maxillary sinus into the alveolar ridge



Roots of upper posterior teeth in close relation with the sinus

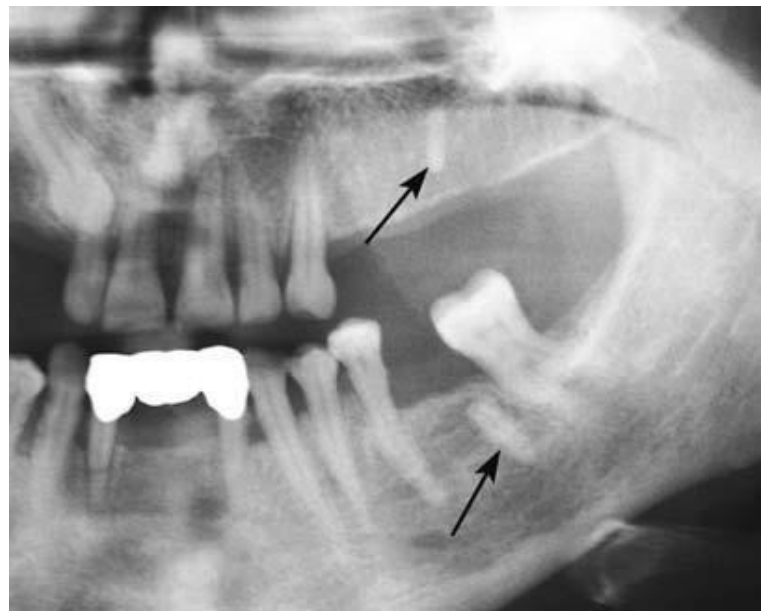


Fusion of maxillary second molar with the third molar in the apical area

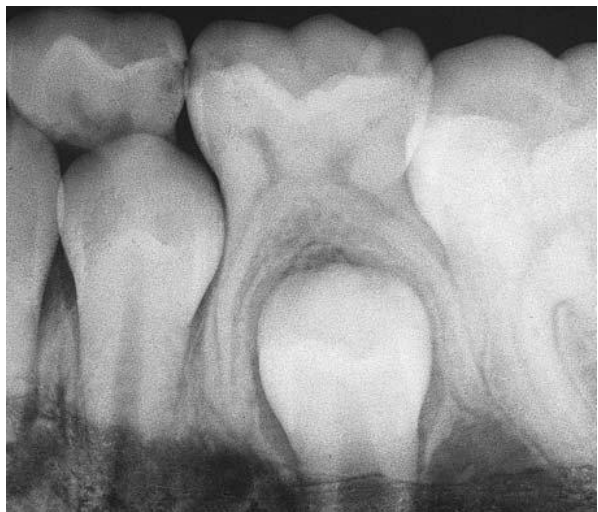8 Broken root tip that have remained in the alveolar bone specially if it is associated with osteolytic lesions, or in such a position that, they could create problems for future prosthesis.

9 Roots with periapical lesions, whose entire removal (for the lesion) through the tooth socket would not be possible with curettage alone .

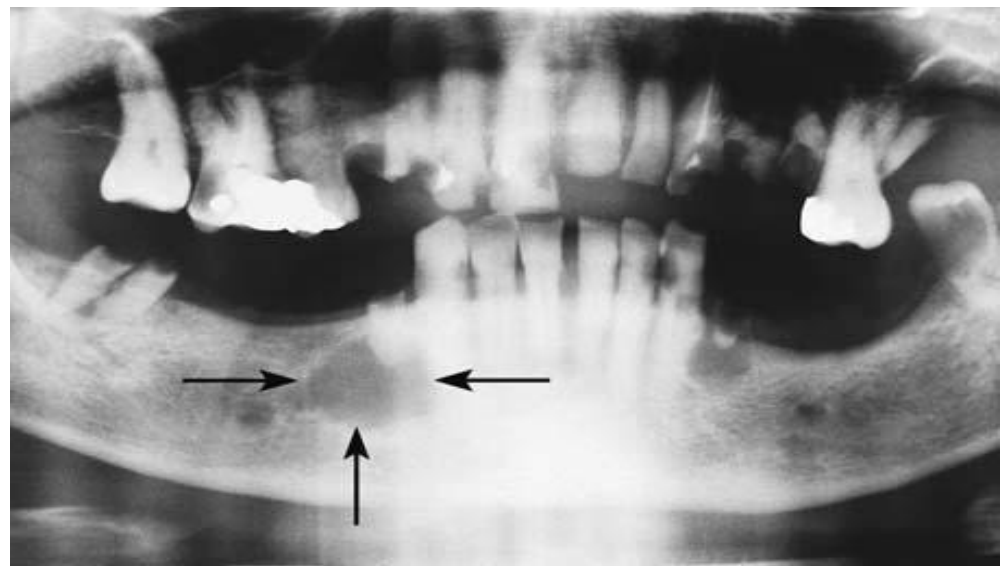
10- Deciduous molars whose roots embrace the crown of the subjacent premolar. If the conventional extraction technique were to be attempted, there is a great risk of extraction of the premolar



Roots of maxillary and mandibular molars completely covered by bone




16 Deciduous molar, whose roots embrace the crown of the succedaneous premolar



Roots with large periapical lesions

Contraindications

**Asymptomatic fractured root tips
Not associated with periapical pathology
Located deep in the socket
Small size root tip (not more than 3-4 mm)**



This extraction should not be done especially in cases when:



1 Dealing with older patients.

2 There is a risk of serious local complications, such as the dislodging of a root tip into the maxillary sinus or injury of the inferior alveolar nerve, mental nerve, or lingual nerve.

3– A large part of the alveolar process needs to be removed.

4– There are serious health problems present.

Steps of Surgical Extraction

Tooth

Root

Creation of a flap

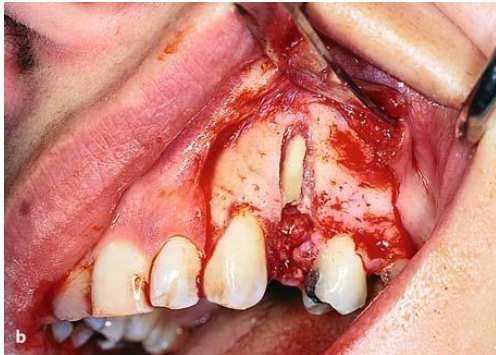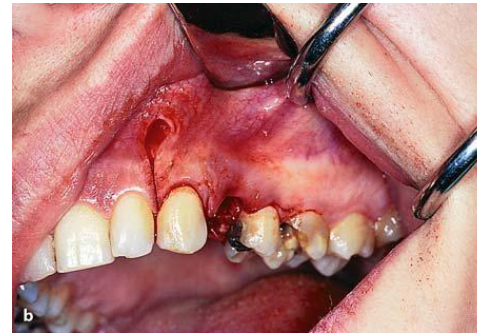
Removal of bone to expose an adequate part of the root

Three techniques:

- A- Removal of part of the buccal bone for luxation of the root buccally.**
- B- Opening of a window on the buccal bone for removal of the root through the socket or through the window itself.**
- C- Creation of a groove on the surface of the root or between the root and bone which allows positioning of the elevator.**

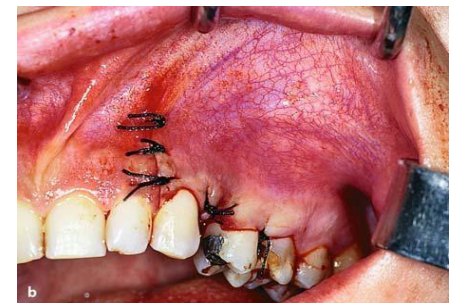
Extraction of the tooth or root with elevators or forceps

Postoperative care of wound and suturing



Note:

Any bone removal by handpiece should be coupled with good irrigation by normal saline.



Surgical Extraction of Teeth

Surgical Extraction of Teeth

1- Flap is made (envelope, 2 or 3 sided).

2- The bone covering the buccal surface of the root (s) is then removed (just below the root bifurcation in multi rooted).

A- In single rooted teeth:

The extraction is performed easily towards the buccal side that is no longer covered by bone, using forceps or elevators.

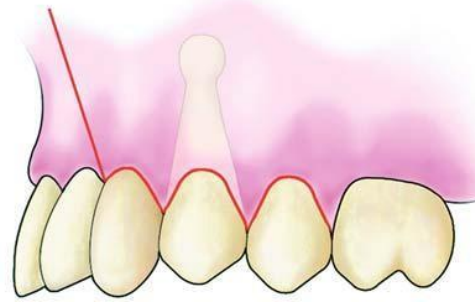
B- In double rooted teeth:

The roots are separated, after a vertical groove is created on the crown using a fissure bur, which extends as far as the intraradicular bone, then each root is removed separately.

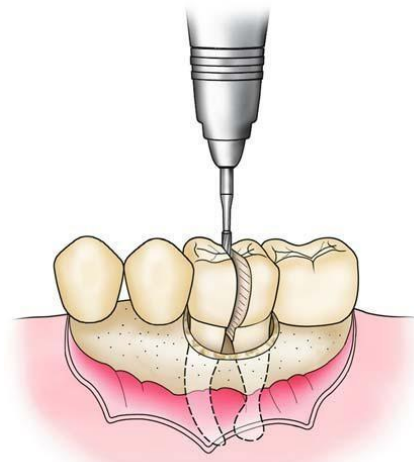
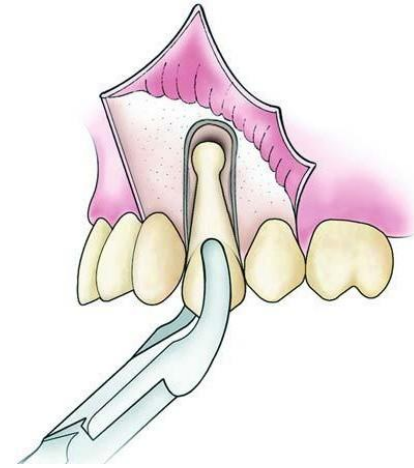
C- In multi rooted teeth:

The two buccal roots are sectioned using a fissure bur, the crown together with the palatal root is removed, then the two buccal roots are removed separately, preferably using a straight elevator or root forceps.

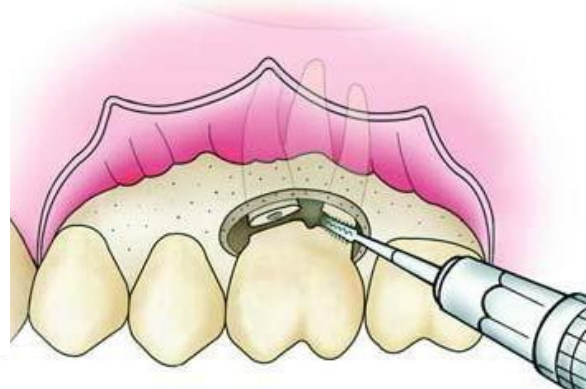
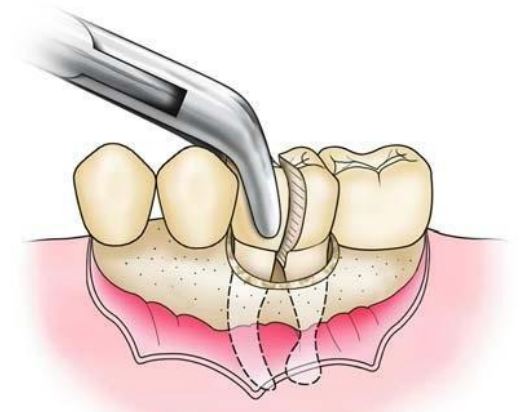
3- The flap is replaced and sutured.



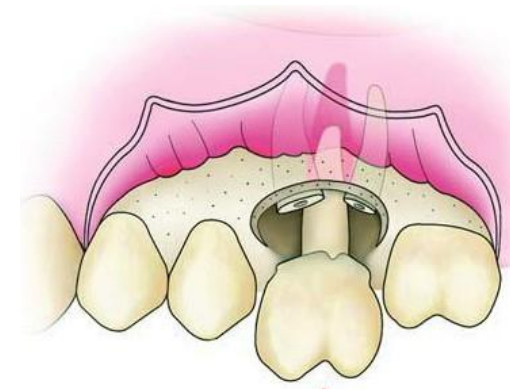
1- Single - Rooted Teeth



2- Double -Rooted Teeth (Mandibular Molars)



3- Multi-Rooted Teeth (Maxillary Molars)



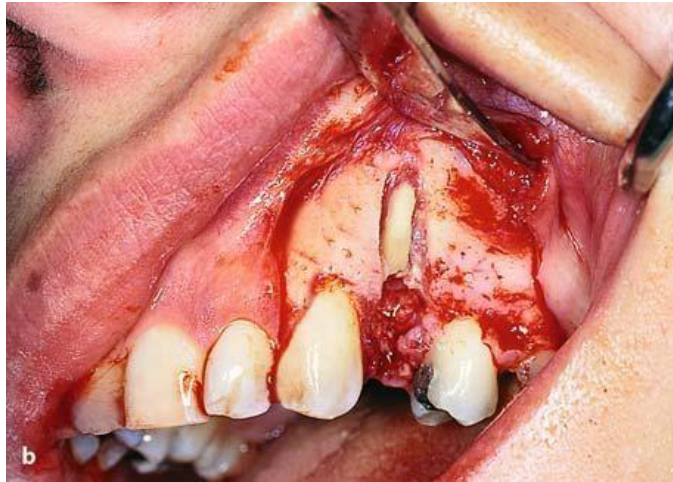

Surgical Extraction of **Root**

Steps of Surgical Extraction

Root

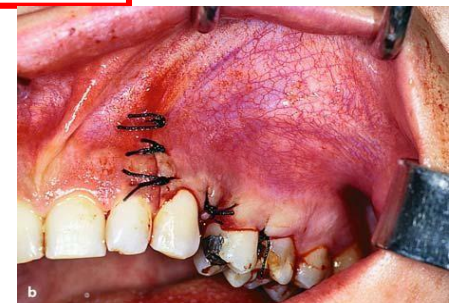
Creation of a flap



Three techniques:
A-Removal of part of the buccal bone.

Extraction of the root with elevators or forceps

Postoperative care of wound and suturing



Note:

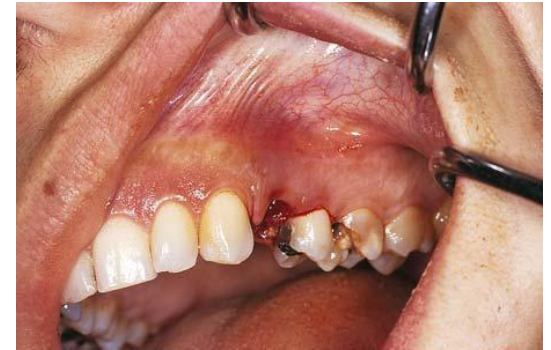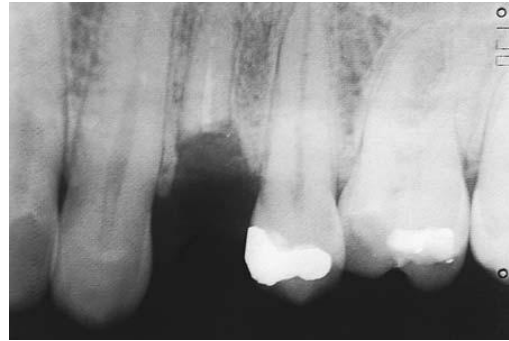Excessive removal of bone should be avoided especially in a patient who is planned for implants.

Surgical Extraction of Root

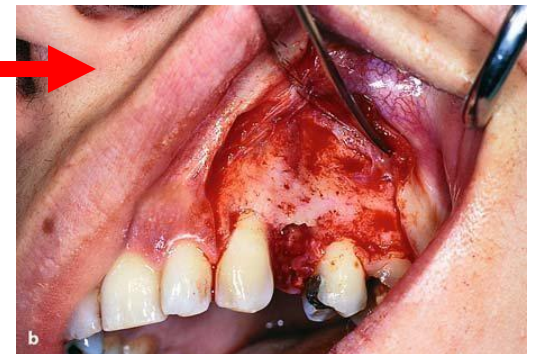
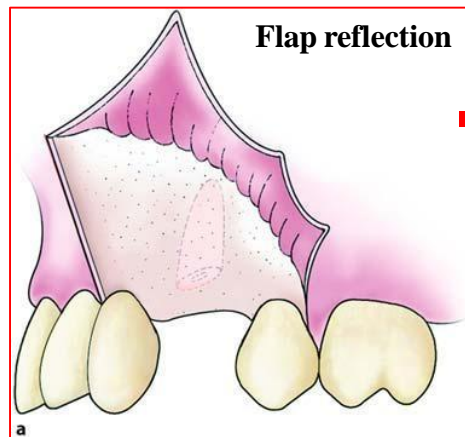
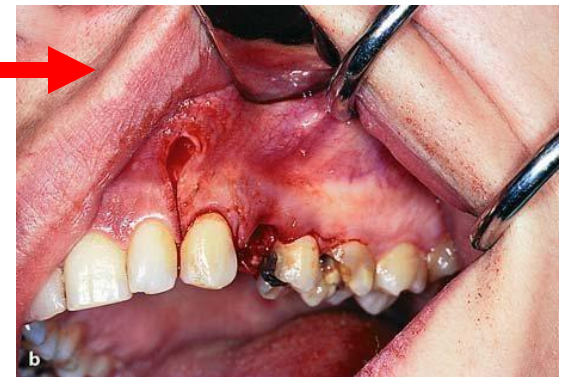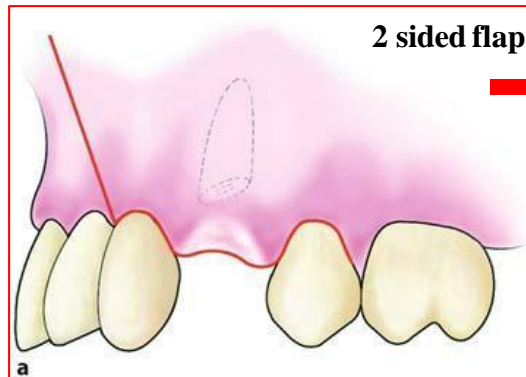
A- After removal of part of the buccal bone

a- Single rooted

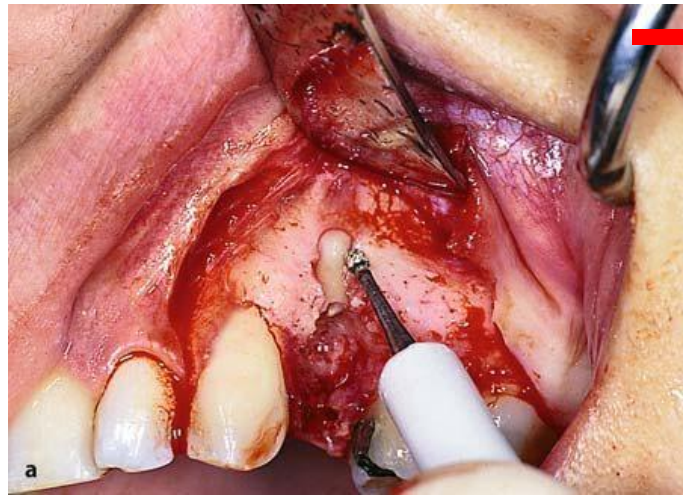1- Flap is made (2 or 3 sided).



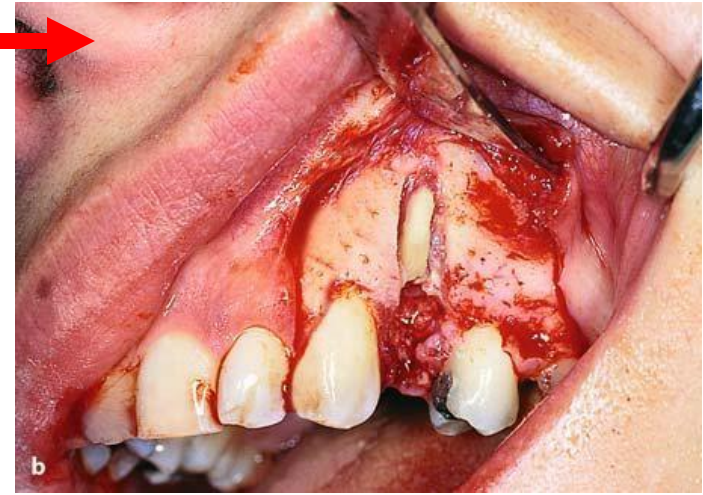2- The mucoperiosteal flap is reflected using periosteal elevator.



3- Part of the buccal bone is removed using a round bur until the root is exposed.

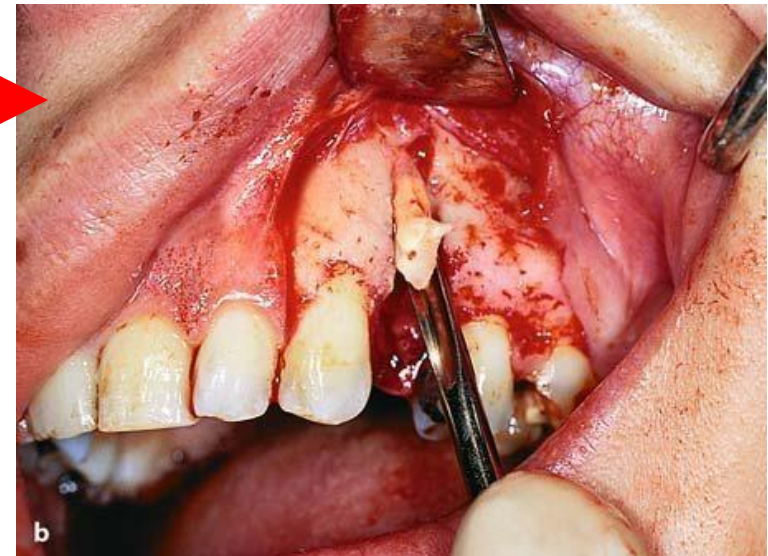
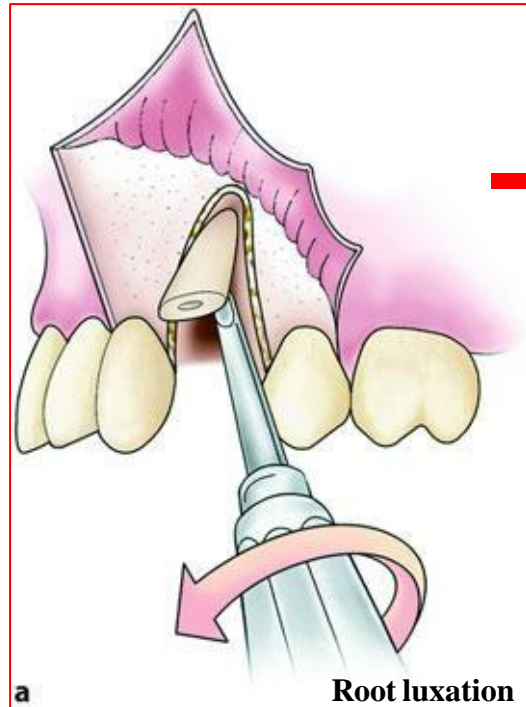


Bone removal

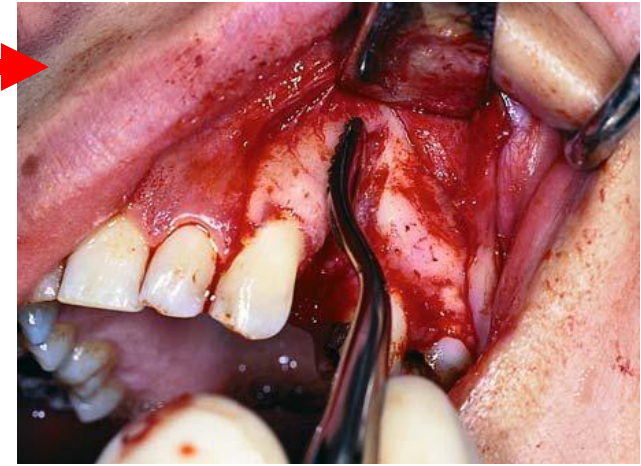
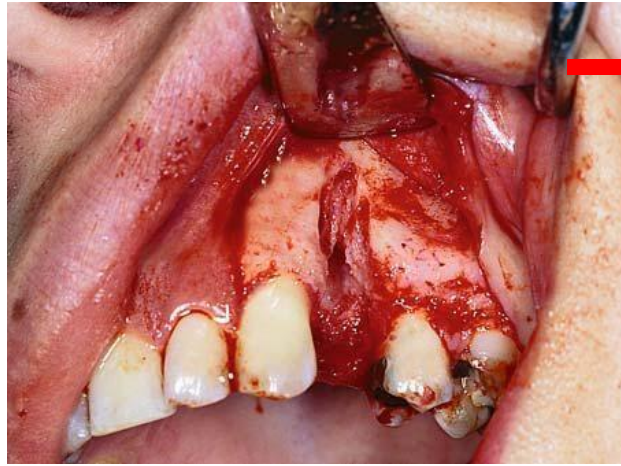
Root exposure

4- The root is then luxated using a straight elevator and removed by applying a small amount of pressure outwards.



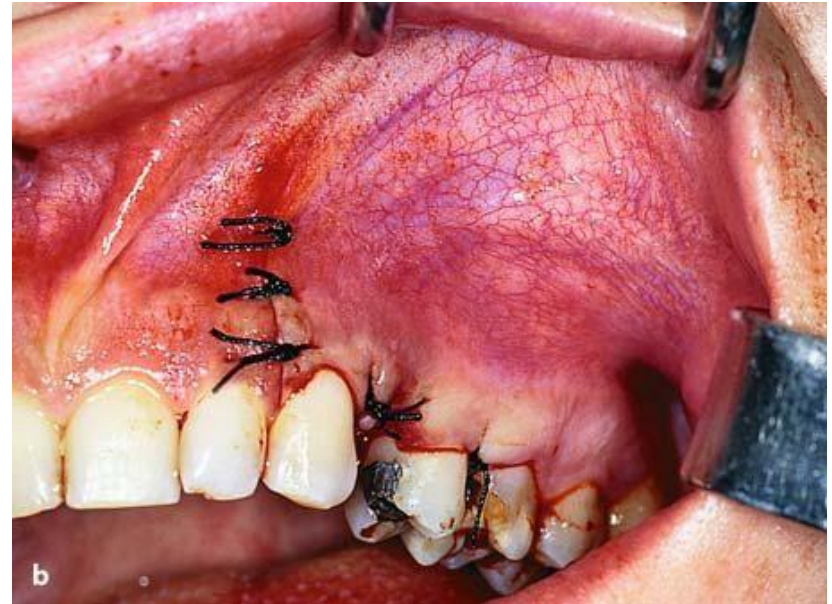
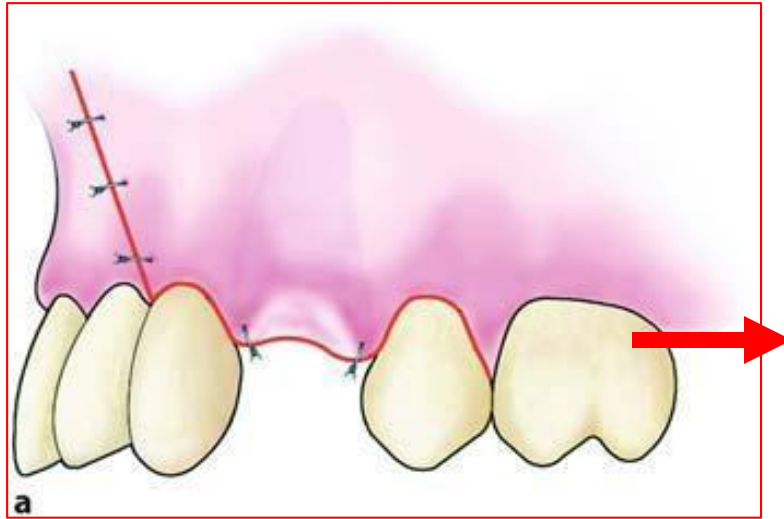
5- After extraction , the surgical site should be inspected, all bony spicules should be removed, any sharp bony edges should be smoothed , sharp areas of bone are assessed by replacing the flap and palpating it with finger. Rongeur or a bone file may be used to smooth these areas.



Root removal

Bone smoothing

6- The surgical field is irrigated with saline solution especially at the area of base of the flap as debris tend to collect in this area.



Suturing

7- Repositioning of the flap and the wound is sutured (simple interrupted suture).

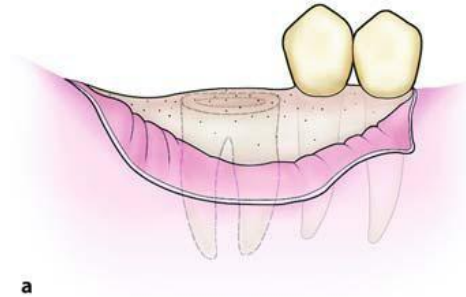
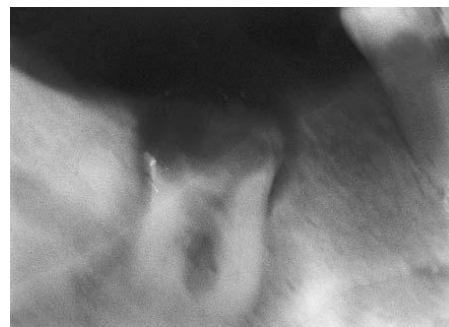
B- Multi rooted:

1 Flap is made (envelope flap or 2 sided), extending one or two teeth, beyond the root to be removed.

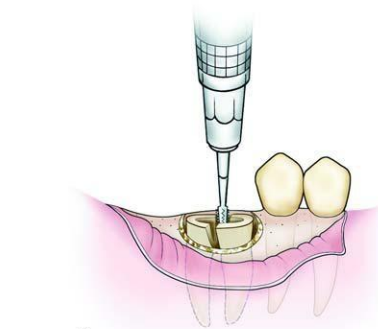
2 Then part of the buccal bone is removed using a round bur, until the root bifurcation is exposed.

3- The roots are sectioned using a fissure bur and are removed with a straight elevator.

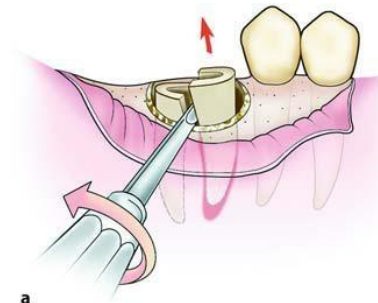
4- The socket is then cared for and sutures are placed.



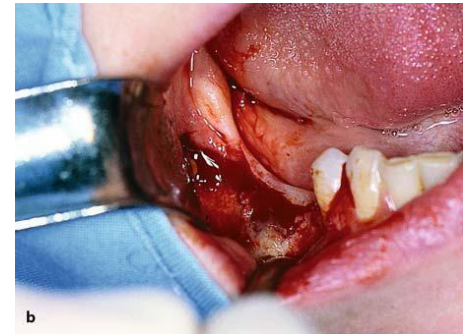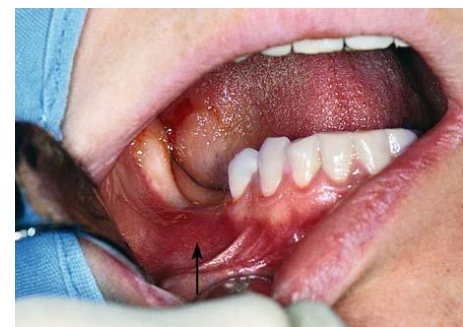a



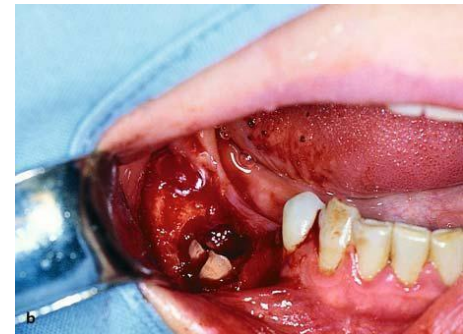a



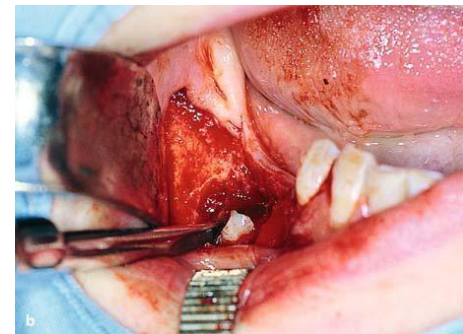
a



b



b

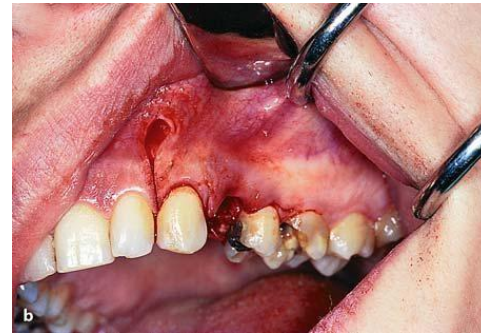

b

Steps of Surgical Extraction

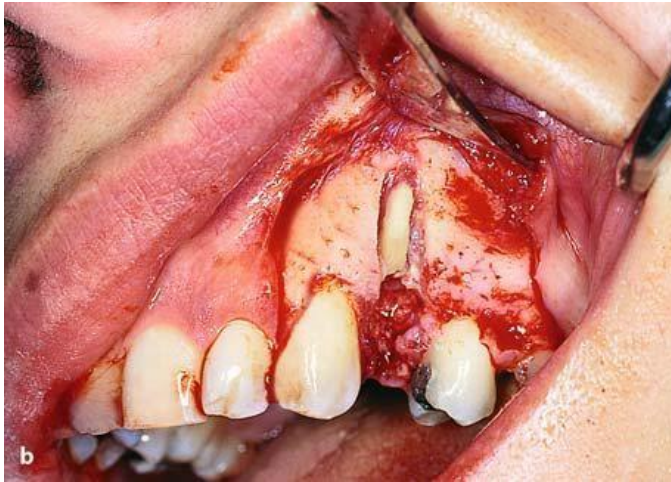Root

Creation of a flap



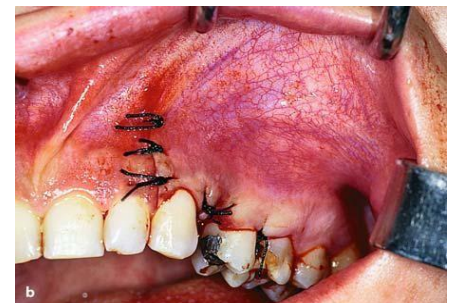
A-Removal of part of the buccal bone.

B- Opening of a window on the buccal bone.



Extraction of the root with elevators or forceps

Postoperative care of wound and suturing



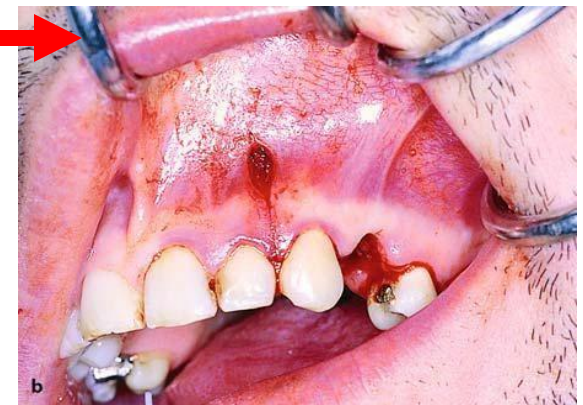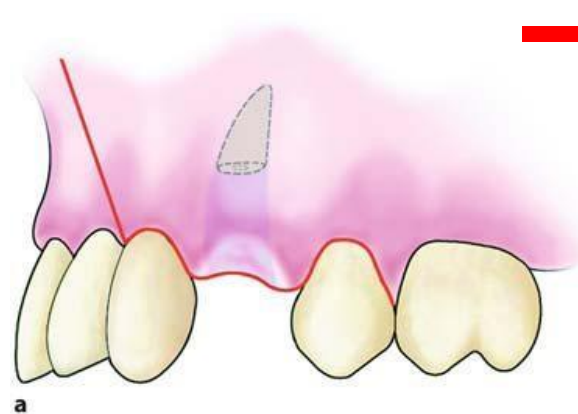
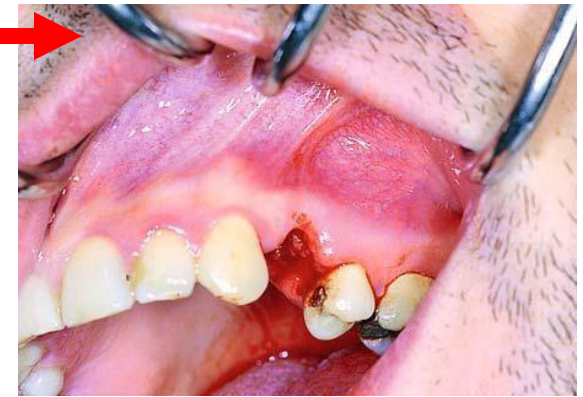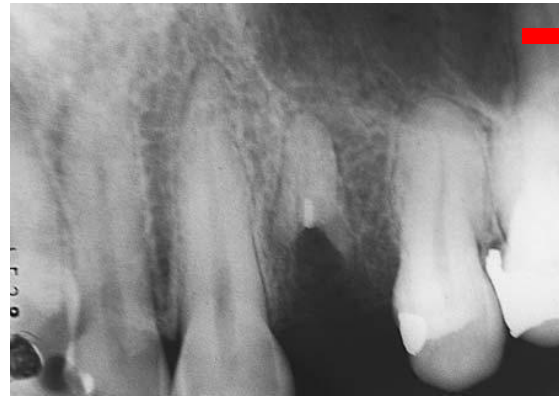Surgical Extraction of Root

B- After a window is created on buccal bone

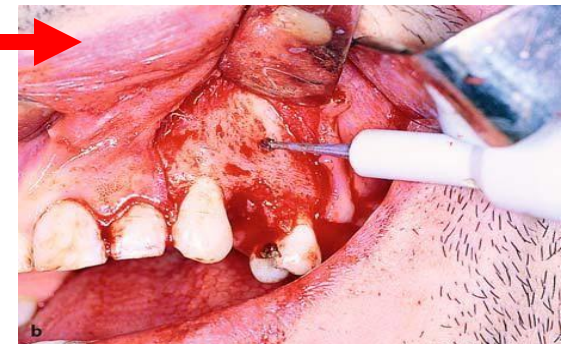
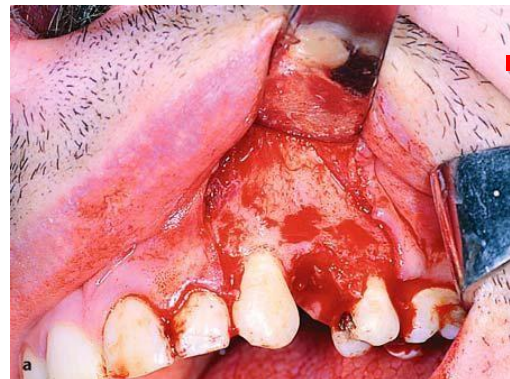In this technique the removal of the root is achieved either through the socket itself or through the window which is created.

a- Root removal through the socket:

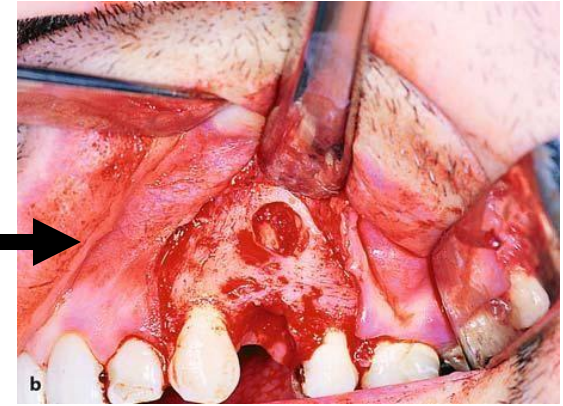
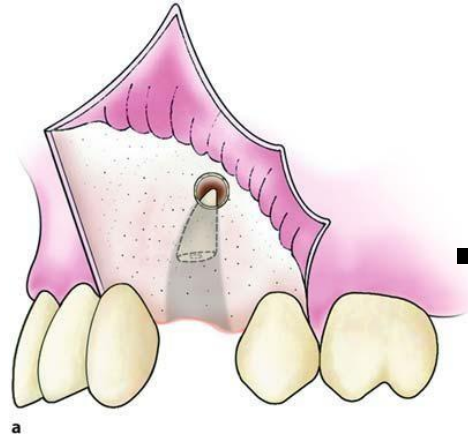
1- Flap is made – 2 or 3 sided flap.



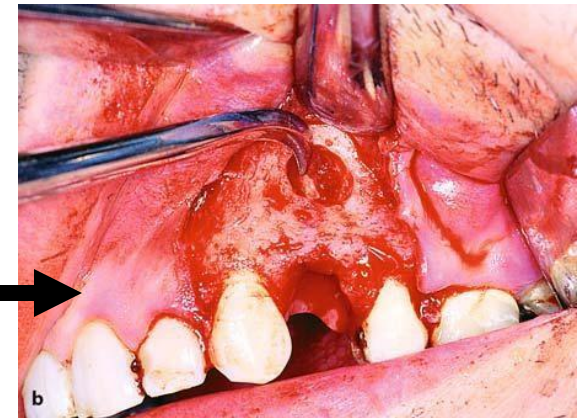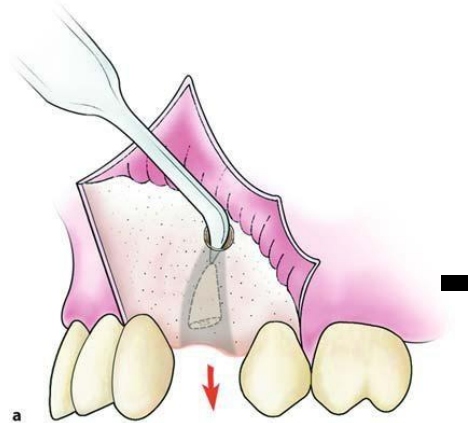
2- Reflection of the mucoperiosteal flap to expose the labial or buccal bone.



3- A small window is created, using a round bur, on the labia/buccal bone corresponding to the tip of the fractured root.

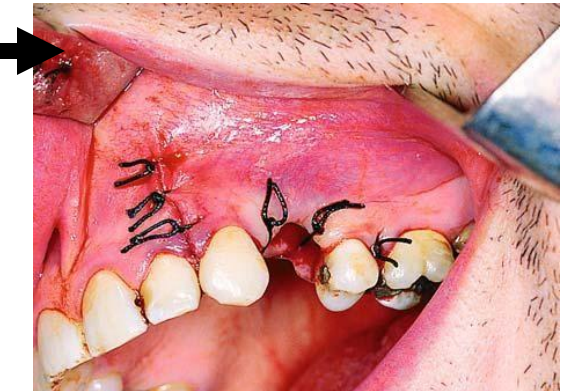
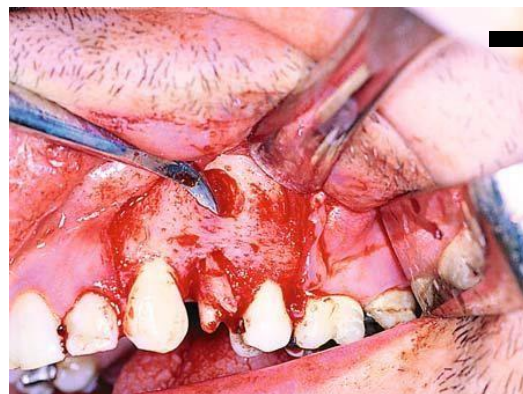
4- The window is then enlarged, and good amount of the root structure is exposed to allow its displacement from the socket using an angled elevator (like apexo or curved warwick james).



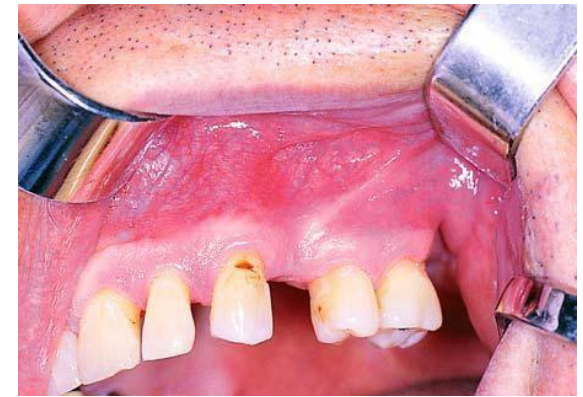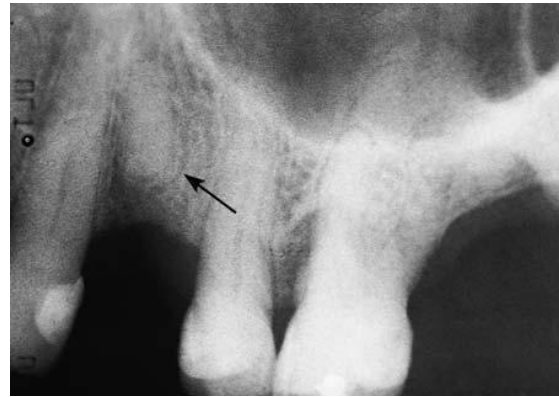
5- After removal of the root, the socket is cared for and interrupted sutures are placed.

This technique is indicated for the removal of roots immediately after their fracture (the socket still open).

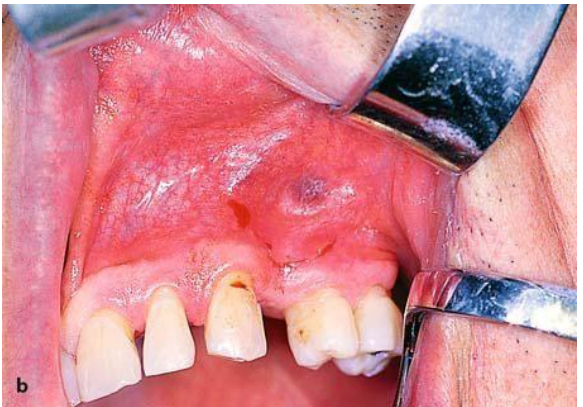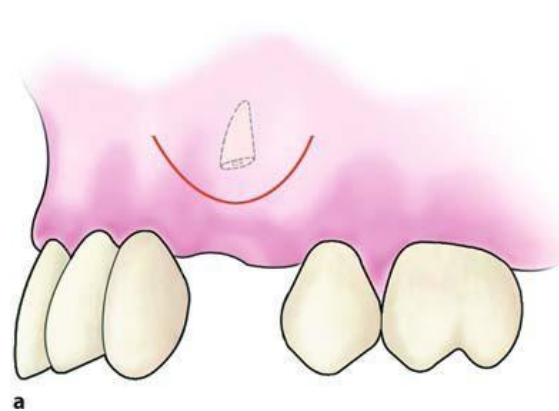


b- Root removal through the window which is created:

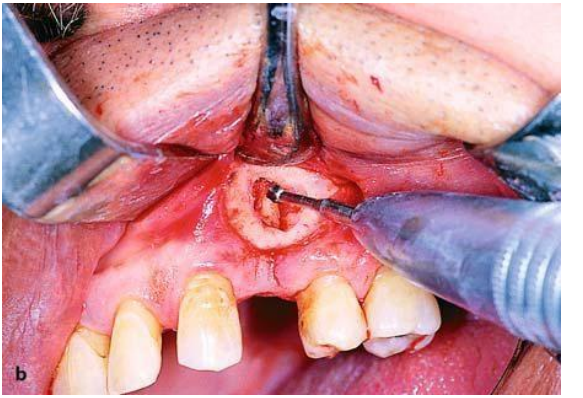
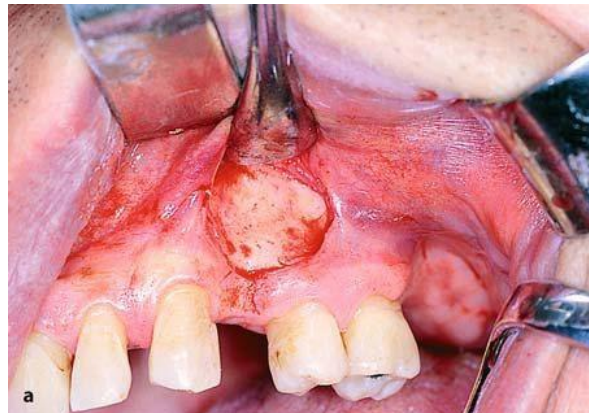
1- A semilunar flap is created.



2- The mucoperiosteal flap is reflected to expose the buccal bone.



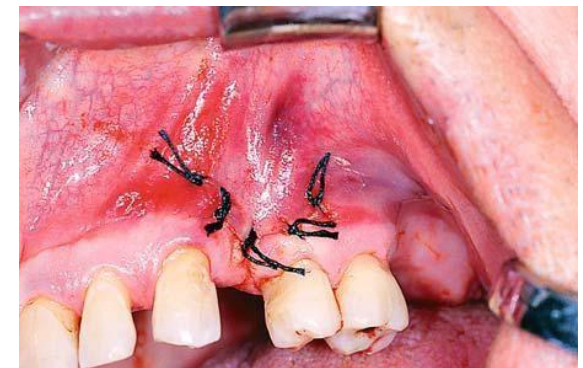
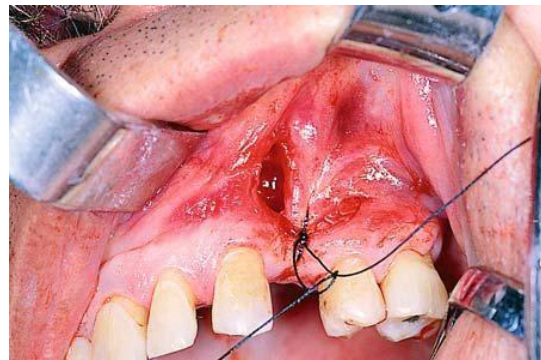
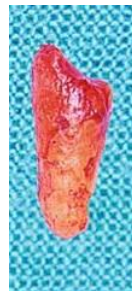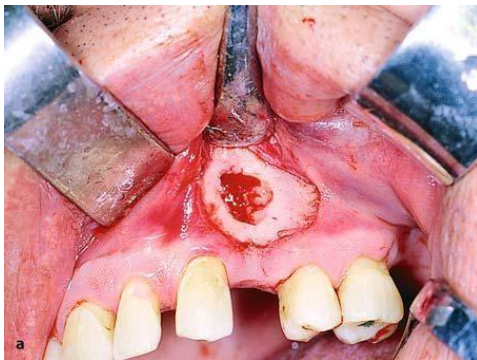
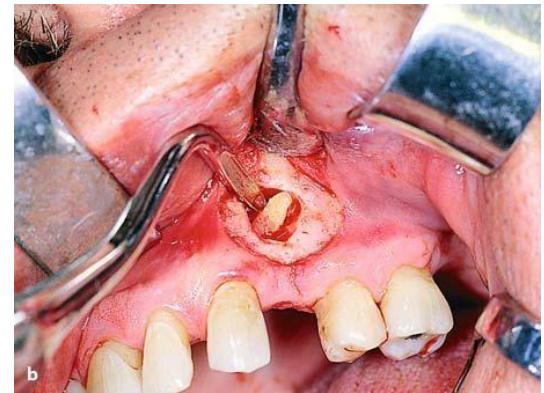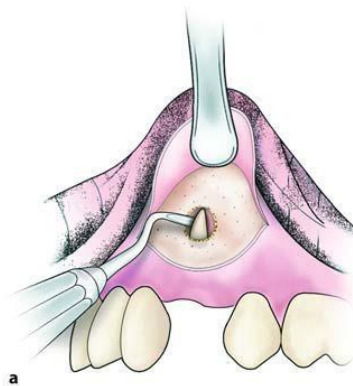
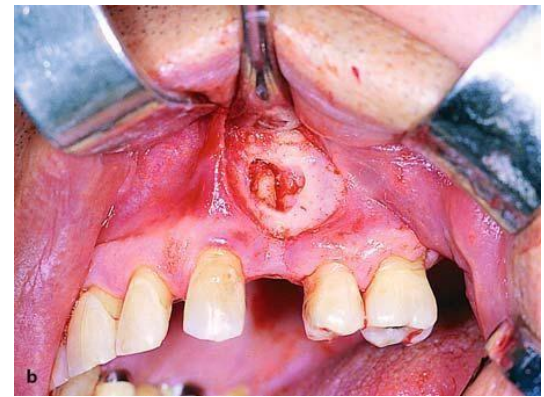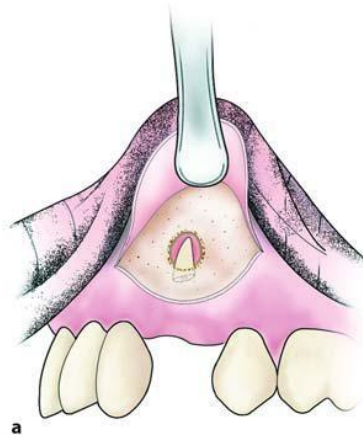
3- A small window is created, using a round bur, on the labial/buccal bone corresponding to the tip of the fractured root.



4The root is then removed from the window without difficulty, preferably using a an angled elevator.

5After removal of the root, the socket is cared for and interrupted sutures are placed.

This technique is usually used in cases of fractured small roots, which were not removed during the extraction procedure but remained in the socket for a long time and were eventually totally covered by bone.



Steps of Surgical Extraction

Root

Creation of a flap



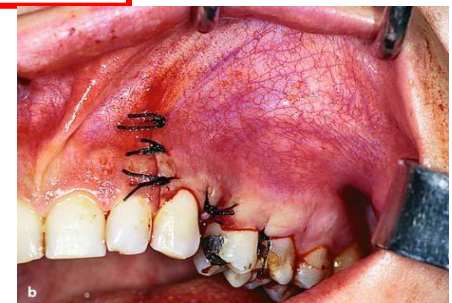
A-Removal of part of the buccal bone.

B- Opening of a window on the buccal bone.

C- Creation of a groove on the surface of the root or between the root and bone.

Extraction of the root with elevators or forceps

Postoperative care of wound and suturing



Surgical Extraction of Root

C- By creation of groove on surface of root or between root and bone, which allows positioning of the elevator.

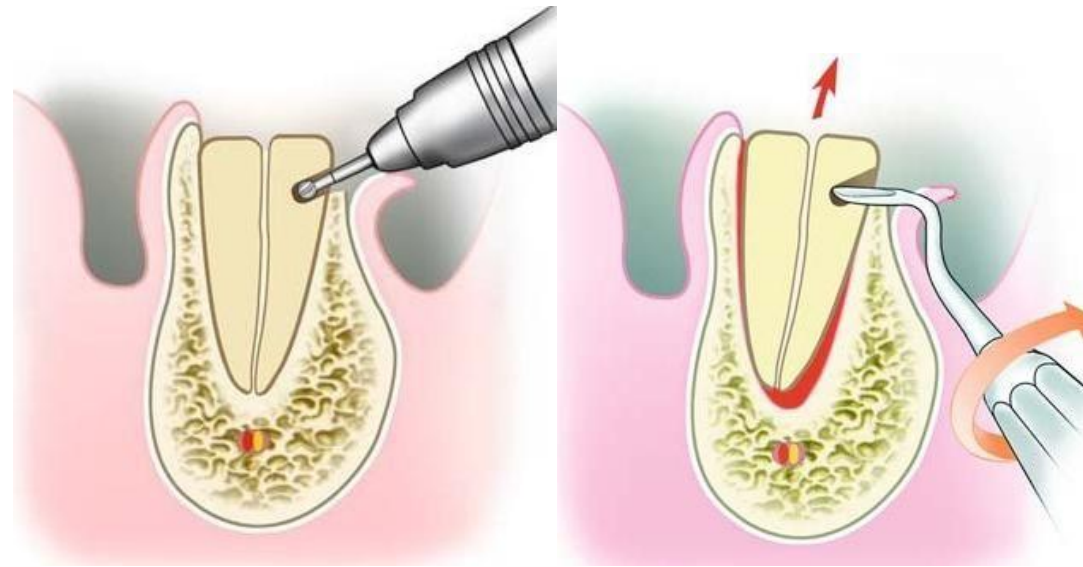
1 Flap is made - envelope or 2 sided flap.

2 Then either:

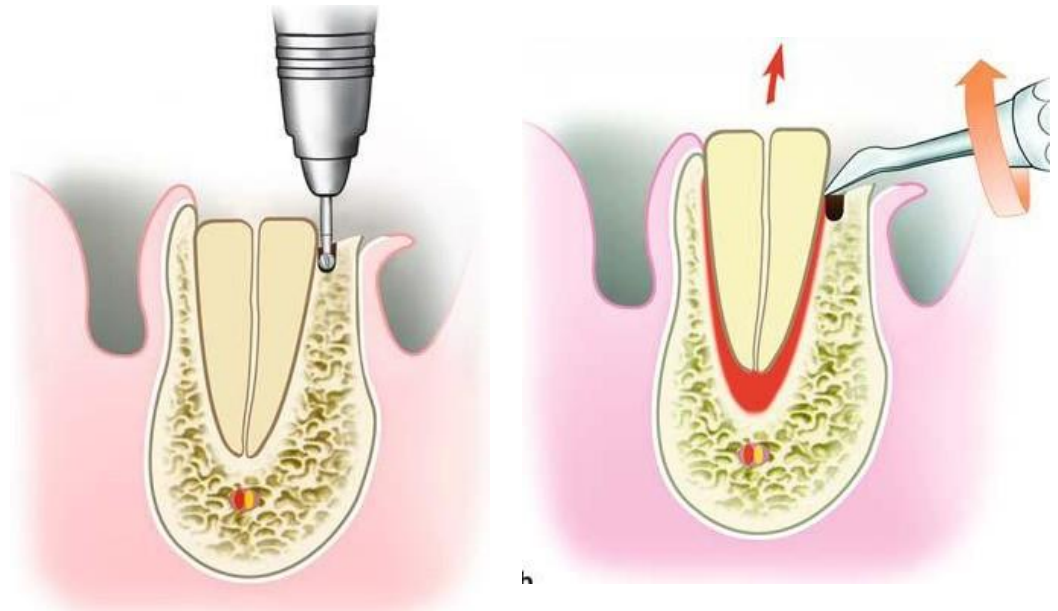
a- A small amount of buccal bone is removed, until part of the root is exposed, a groove is then created on root surface, which allows positioning of the blade of the elevator, to luxate the root outwards.

b- A groove is created using a round bur between the buccal bone and the root, which makes enough room to allow for the positioning of the elevator, the blade of the elevator (straight or cryer's elevators) is then seated in the groove, which luxates the root upwards.

This technique is used in the lower posterior teeth, where the buccal bone serves as a fulcrum, is dense and able to withstand applied pressure.

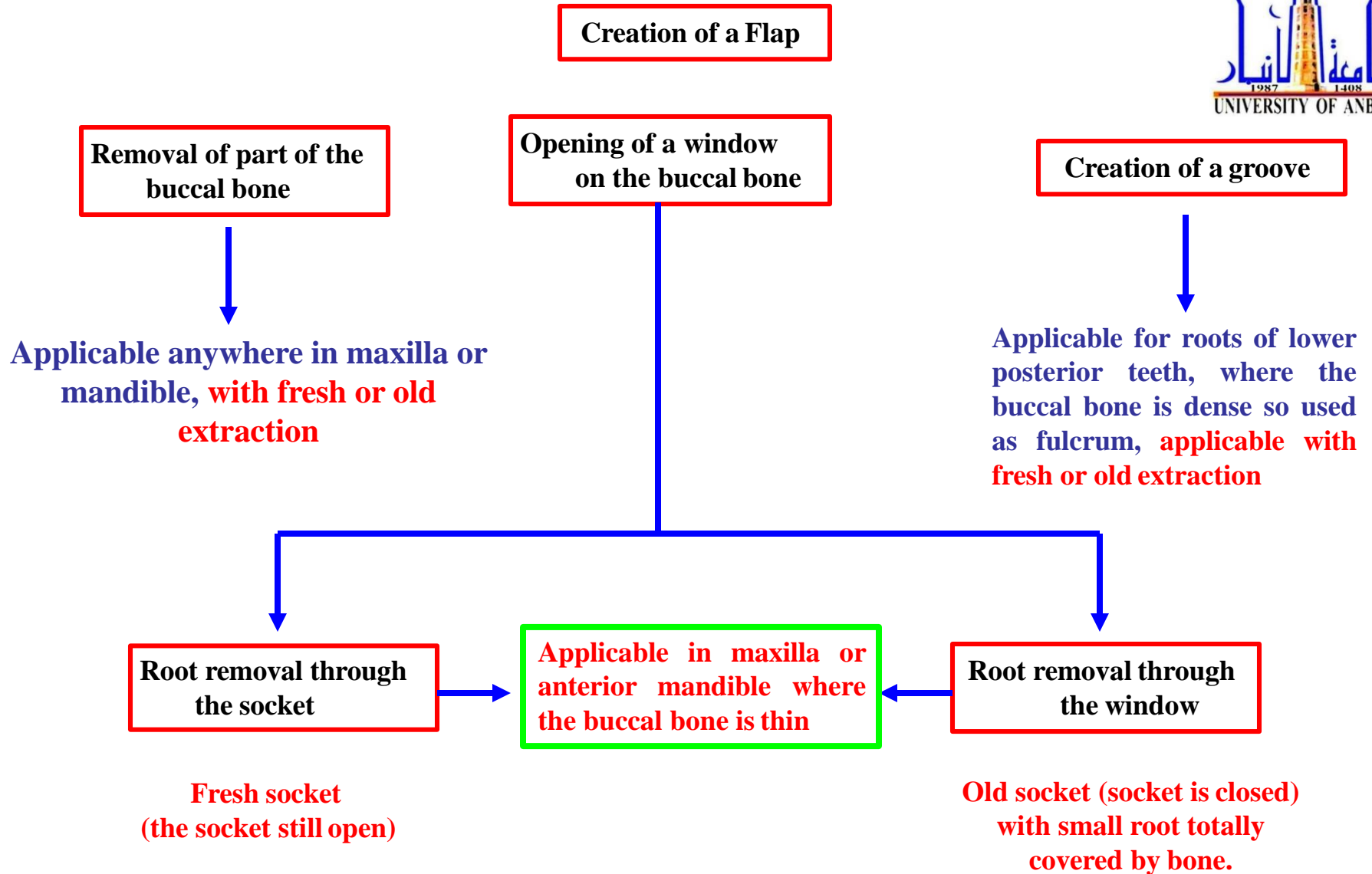


Creation of groove on surface of root



Creation of groove between root and bone

Summary of Surgical Extraction of Root



Dr. Hamid Hammad Enezei
PhD

Oral & Maxillofacial Surgery



Thank You